



Nail Fold Capillary Abnormality and Insulin Resistance in Children with Familial Mediterranean Fever: Is There Any Relationship Between Vascular Changes and Insulin Resistance?

ORIGINAL
ARTICLE

İsmail Dursun¹, Sebahat Tulpar¹, Sibel Yel¹, Demet Kartal², Murat Borlu², Funda Baştuğ¹, Hakan Poyrazoğlu¹, Zübeyde Gündüz¹, Mehmet E. Yüksel³, Kader Köse⁴, Abdulağ Çalıışkan³, Ahmet B. Cekgeloglu³, Ruhan Düşünsel¹

ABSTRACT

Objective: Nail fold capillary changes are accepted as early symptoms of several rheumatic disorders such as scleroderma and dermatomyositis. In adults, nail fold capillary abnormality (NCA) has been described in Familial Mediterranean Fever (FMF). However, there is not enough study in children with FMF. The aim of the present study was (1) to investigate whether children with FMF have NCA in both active and/or remission period or not and (2) to assess insulin resistance in children with FMF in both active and/or remission period of the disease compared with the control group.

Materials and Methods: Ninety-two patients with FMF, including 25 patients in the active period and 67 patients in the remission period, and 33 apparently healthy children were enrolled in the study. Nail fold capillary examination was performed. Groups were compared for inflammatory markers (erythrocyte sedimentation rate, C-reactive protein, and serum amyloid A (SAA)), insulin resistance (homeostatic model assessment of insulin resistance, HOMA-IR), and NCA. The relationship among the NCA, insulin resistance, and inflammatory markers was evaluated.

Results: Overt NCA was found in 20% of patients at the attack period and in 2.9% of patients in remission. HOMA-IR was higher at the attack period than at the attack-free period and control. However, this did not reach statistical significance. Nevertheless, HOMA-IR was positively correlated with SAA. The NCA was significantly positively correlated with increased levels of acute-phase reactants and was significantly negatively correlated with serum high-density lipoprotein levels.

Conclusion: There are apparent NCA in children with FMF especially in the active period of the disease. There is insulin resistance that is likely associated with inflammation. The NCA becomes overt in the active period of the disease as insulin resistance.

Keywords: Familial mediterranean fever, nail fold capillary abnormality, insulin resistance

Cite this article as:
Dursun İ, Tulpar S, Yel S, Kartal D, Borlu M, Baştuğ F, et al. Nail fold capillary abnormality and insulin resistance in children with familial Mediterranean fever: is there any relationship between vascular changes and insulin resistance? Erciyes Med J 2018; 40(2): 70-4

¹Department of Pediatric Nephrology, Erciyes University Faculty of Medicine, Kayseri, Turkey

²Department of Dermatology, Erciyes University Faculty of Medicine, Kayseri, Turkey

³Department of Electronics Engineering, Erciyes University Faculty of Engineering, Kayseri

⁴Department of Biochemistry, Erciyes University Faculty of Medicine, Kayseri, Turkey

Submitted
07.03.2018

Accepted
21.03.2018

Correspondence

İsmail Dursun,
Department of Pediatric Nephrology, Erciyes University Faculty of Medicine, Kayseri, Turkey
Phone: 0352 207 66 66
e-mail: drdursun@hotmail.com

©Copyright 2018
by Erciyes University Faculty of Medicine - Available online at
www.erciyesmedj.com

INTRODUCTION

Familial mediterranean fever (FMF) is an autosomal recessive autoinflammatory disease characterized by recurrent fever, serositis, and erysipelas-like erythema. In previous studies, several types of vasculitis, especially IgA vasculitis (previously called Henoch-Schönlein purpura) and polyarteritis nodosa, were found to occur more commonly in patients with FMF (1-2). Recently, structural changes in the nail fold capillaries of patients who have vascular inflammation have been detected (3).

Inflammation causing endothelial dysfunction plays a major role in the development of atherosclerosis (3). In adult studies, it was shown that patients with FMF have significantly increased carotid intima-media thickness, which is commonly used for the non-invasive evaluation of carotid atherosclerosis in various diseases and general population, and fasting plasma blood glucose levels compared with control subjects (4-7).

Although there is no general agreement, it was determined that overt or subclinical inflammation in FMF may cause insulin resistance (8). To our knowledge, there is no study on this issue in children. In some diseases accompanied by vascular inflammation, structural changes were demonstrated in the nail fold capillaries of patients (9). In the literature, there are only two adult studies for nail fold capillary changes in patients with FMF, and these studies demonstrated the presence of nail fold capillary changes in patients with FMF (10, 11). To the best of our knowledge, this is the first study that evaluates nail fold capillary changes in children with FMF.

In the present study, we aimed to investigate whether children with FMF have nail fold capillary abnormalities (NCAs) in both active and/or remission period or not and to assess insulin resistance in children with FMF in both active and/or remission period of the disease compared with the control group.

MATERIALS and METHODS

General Information

This cross-sectional study included 92 patients with FMF (25 in the active period and 67 in the remission period) and 33 healthy controls. Children aged between 7 and 17 years old were included in the study. The study was approved by the ethics committee of Erciyes University Medical Faculty (2011/304). All study procedures were conducted in accordance with a protocol previously approved by the Institutional Review Board of Erciyes University. Informed consent was obtained from children and their parents. A complete physical examination including anthropometric measurements was performed in all of the children. Reference body mass index curves for Turkish children 6 to 18 years old were used to determine obese children who were excluded from the study (12). Fasting blood samples in the patient and control groups were extracted in order to determine insulin, blood glucose, lipids, and acute-phase reactants (erythrocyte sedimentation rate (ESR), C-reactive protein (CRP), and serum amyloid A (SAA)). For SAA, the samples were placed in a standard biochemistry tube, centrifuged, and stored at -70°C until analysis. SAA was analyzed using a standard nephelometric method according to the manufacturer's instructions. Based on fasting glucose and insulin values, homeostatic model assessment of insulin resistance (HOMA-IR) was calculated using the following formula: $\text{HOMA-IR index} = [\text{serum insulin } (\mu\text{U/mL}) \times \text{fasting plasma glucose (mg/dL)} / 405]$ (13). In addition, insulin resistance was evaluated.

Dyslipidemia was diagnosed if one or more of the following features are presented: (1) hypertriglyceridemia, (2) low high-density lipoprotein (HDL) cholesterol (<35 mg/dL), and (3) hypercholesterolemia. Hypertriglyceridemia was defined as a triglyceride level >105 mg/dL for children below 10 years old and >136 mg/dL for children ≥ 10 years old. Hypercholesterolemia was defined as a high total cholesterol >95 th percentile for age and sex (14). Dyslipidemia was defined if any of the following features are presented: (1) elevated triglyceride, (2) low HDL cholesterol (<35 mg/dL (<0.9 mmol/L)), and (c) high total cholesterol (>95 th percentile) (14).

Procedures

In patients and controls, an experienced dermatologist physician, who was blinded to the clinical diagnosis of the patient, made a nail fold capillary examination using a standard dermatoscope. Each patient rested in a test room with a room temperature of 20°C – 22°C for 15 min. Eight nails except the nail of the hand's first finger were examined. The video camera of the dermatoscope was placed on the nail fold of each finger using a transparent gel between the probe and the area in order to improve image resolution, and a photograph was taken. The photos were then evaluated by an academician, who has never seen the patients and controls and who had no information about the clinics of the patients (Prof. Murat Borlu, MD), from the Department of Dermatology. The enlargement or tortuosity of the capillaries was accepted as vascular abnormality (Figure 1). Subsequently, to control our dermatoscope findings in children with apparent NCA, the dermoscopic images of the patients are also evaluated by using image processing and statistical methods employing texture detection, statistical moment calculation, and k-means classification algorithm. This method is

based on the selection of a region around the nail fold for each picture as shown in Figure 1. The selected regions are converted to grayscale image before the texture of the grayscale image is obtained. The standard deviations (SDs) of the selected regions are evaluated for 100 cases by using the MATLAB program after the texture of the grayscale image is obtained. The SDs of the selected regions are clustered by using the k-means clustering method into three clusters. These clusters are classified as normal cases, uncertain cases, and certain cases.

1. Normal cases labeled zero (0) have the lowest SD among the three clusters.
2. Uncertain cases labeled one (1) have higher SD than normal cases.
3. Certain cases labeled two (2) have the highest SD among the other cases.

Image Texture

Haralick and Shapiro (15) defined texture as the uniformity, density, coarseness, roughness, regularity, intensity, and directionality of discrete tonal features and their spatial relationships. Image texture gives us information about the spatial arrangement of color or intensities in an image or selected region of an image (16). The texture of the grayscale images is used to evaluate the SD of the selected region instead of grayscale images in the present study because the texture of the grayscale images is more suitable for this purpose (Figure 2).

k-Means Clustering

Clustering of a set of data into smaller subsets is a commonly used technique in applications such as pattern recognition, statistics, data mining, and image processing (17). The problem that must be solved is partitioning a set of data into smaller homogeneous groups of data, called clusters, where data points in the same group have closer/similar properties. There are various algorithms proposed to solve the clustering problem, and k-means clustering algorithm is one of the most popular (18). Briefly, it is simply based on assigning every entry in the data into a cluster, based on its distance from the centers of the clusters (18).

Statistical Analysis

All tests were performed using the SPSS for Windows 15.0 (SPSS, Chicago, IL, USA). First, the distributions of all parameters were determined using the Kolmogorov–Smirnov test. The parameters with normal distribution were expressed as mean \pm SD, and the parameters with non-normal distribution were expressed as median (minimum–maximum). The comparisons of means were performed by the Student's t-test. The comparisons of medians were performed using the Mann–Whitney U test. The comparisons of proportions were performed with the χ^2 test. The comparisons between the three groups for the parameters with normal distribution were made using ANOVA with the post hoc Tukey procedure and Kruskal–Wallis H test for the parameters with non-normal distribution.

In the study population, univariate logistic regression analyses were performed by designating NCA as a dependent variable and ESR, CRP, SAA, HDL, white blood cell (WBC) counts, and HOMA-IR as independent variables. A p-value <0.05 was considered to be significant.

RESULTS

No statistically significant difference was detected between the patients and controls in terms of age, gender, BMI, blood pressures, and triglyceride and cholesterol levels. Serum glucose level was statistically higher in the active period of FMF than in the control group (Table 1). HOMA-IR was higher at the attack period than at the attack-free period and control. However, it did not reach statistical significance (Table 1). HDL cholesterol level was statistically lower in the active period of FMF than in the control group. As expected, WBC, ESR, CRP, and SAA levels were significantly higher in the active period of FMF than in the remission of FMF and control groups.

We determined NCA in five of the children with FMF during the attack and in two of the children with FMF during the attack-free period.

None of the healthy controls had any NCA. The NCA was verified by using an image processing and was detected in 2 of the 5 children who have vascular abnormality in the active FMF group and in 1 of the 2 children who have vascular abnormality in the FMF remission group. We did not detect any capillary abnormality in the control group. These results were verified using image processing, statistical methods employing texture detection, statistical moment calculation, and k-means classification algorithm (Figure 1 and 2). The number of children with the NCA was significantly higher in the attack period than in the attack-free period and in the healthy controls.

No correlation was detected between nail fold capillary changes and HOMA-IR, which is a marker of insulin resistance. Having NCA was significantly positively correlated with inflammatory markers and was significantly negatively associated with HDL. A

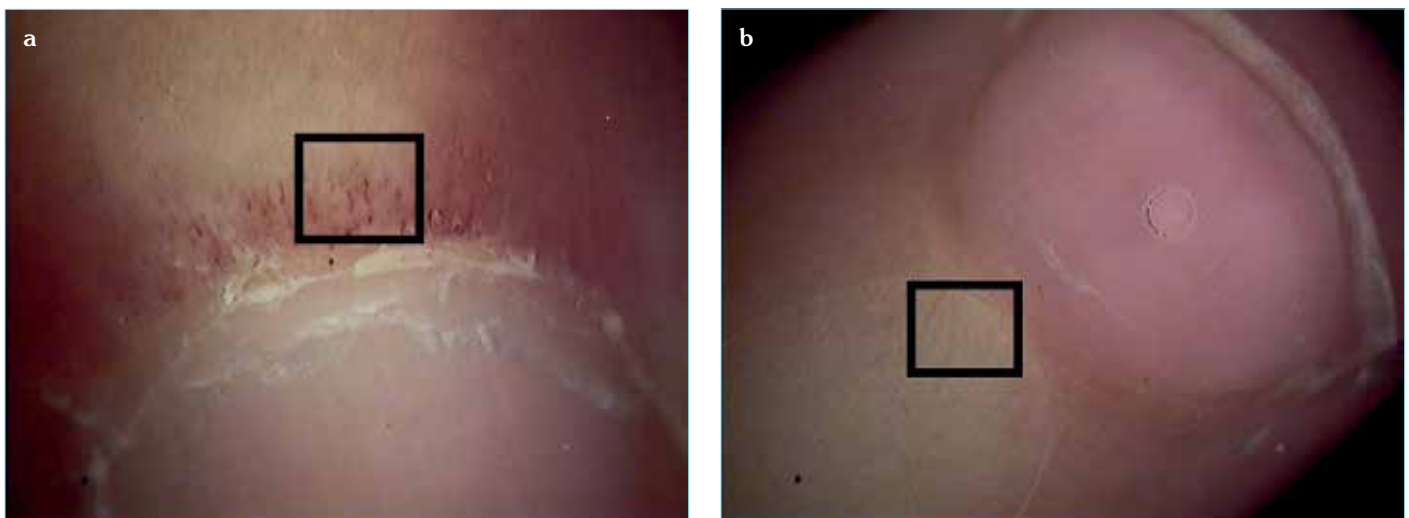


Figure 1. a, b. (a) Certain case (b) Normal case



Figure 2. The image processing

Table 1. Parameters of insulin resistance and nail fold capillary abnormalities in the study groups.

Variables	FMF attack (n = 25)	FMF remission (n = 67)	Control (n = 33)	p
Fasting blood glucose (mg/dL)	90±11	86±9	82±9	0.02
Insulin (mIU/mL)	3.2 (2.0–35.9)	2 (2.0–9.5)	2.7 (2.0–42)	0.01
HOMA-IR	0.78 (0.37–11.1)	0.44 (0.30–2.24)	0.59 (0.37–6.56)	0.08
Nail fold capillary abnormalities	5	2	0	0.01

HOMA-IR; homeostatic model assessment of insulin resistance

significant positive correlation was detected between HOMA-IR and SAA ($r=0.165$, $p=0.039$) (data not shown).

No difference was detected between the patient groups in terms of the distribution of MEFV mutation. Furthermore, it was found that being a carrier of homozygous or compound heterozygous mutation is not a facilitating factor for NCA (data not shown).

DISCUSSION

The present study demonstrated that there were apparent NCAs in children with FMF especially in the active period of the disease, and there was insulin resistance that is likely associated with inflammation.

Insulin resistance is defined as the development of resistance against the ability of insulin to mediate the intake of glucose to the peripheral tissues and is an important process in the development of type 2 diabetes (19). Pyyri is a major player in the maturation and secretion of interleukin (IL)-1 β , which is responsible for inflammatory manifestations of FMF (20). One of the major sources of chronic inflammation seen in obesity is the NOD-like receptor family pyrin domain containing 3 (NLRP3) inflammasome, which is a well-known inflammasome-producing IL-1 β in answer to metabolic and infectious stimuli (21, 22). Similarly, pyrin and its mutant forms in FMF may cause uncontrolled IL-1 β production via both NLRP3-dependent and independent pathways (23). In the literature, there are only two adult studies addressing insulin resistance in patients with FMF. Sarkis et al. (8) demonstrated that patients with FMF have increased levels of HOMA-IR, insulin, and fasting glucose. On the contrary, Ugurlu et al. (24) could not show any difference between the patients with FMF and controls in terms of insulin resistance. As later study results, we did not find overt insulin resistance in children with FMF. However, a significant positive correlation was detected between HOMA-IR and SAA. This correlation may be associated with high levels of HOMA-IR especially in patients with FMF during the attack period. In our study, the exclusion of obese children from the study and control groups owing to the likelihood of an effect on insulin resistance suggested that the role of FMF in the formation of insulin resistance was limited.

The diseases causing chronic inflammation may play a key role in the development of atherosclerosis, diabetes, and autoimmune diseases (25). Obesity might be one of the serious complications of chronic inflammatory diseases secondary to decreased physical activity and steroid toxicity. In a study from the USA, of the children with juvenile idiopathic arthritis, 18% were obese, and 12% were overweight (26). In a retrospective study performed in children with FMF, 12.8% of the subjects were overweight, but none of the patients had obesity (27).

Some structural changes in nail fold capillaries were demonstrated in some diseases, leading to vascular inflammation (10, 11, 28, 29). In a study by Aytakin et al. (11), 31 patients with FMF who had no any evidence of vasculitis and 30 controls were evaluated in terms of NCAs, and focal dilatation was found in 5 patients and microhemorrhage was found in 1 patient. They claimed that microvascular abnormalities found in patients with FMF likely result from amyloidosis and vasculitis. Although the pathogenesis of vasculitis in FMF remains unclear, it has been postulated that immune complexes may play a pivotal role (30). As shown by Aytakin et al. (11),

Dinc et al. (10) investigated the NCA in 59 adult patients with FMF and found tortuosity in 17 patients, extravasation in 14 patients, and dilatation in 9 patients. The nail fold capillary changes were more commonly seen in patients with FMF accompanied by Raynaud's phenomenon (RF) (4). In our study, marked changes of the nail fold capillary bed were detected in 5 patients with FMF in the active period and 2 in the remission group (Figure 1). None of our patients had a history of RF. These findings demonstrate that patients with FMF may have nail fold capillary changes especially in the active period of the disease. To our knowledge, this is the first study to evaluate the relationship between nail fold capillary changes and inflammatory and metabolic markers overt in the active period of the disease as insulin resistance. Our study results showed that vascular changes observed in the nail fold capillary bed become overt in the active period of the disease as insulin resistance. However, as our study did not include a nail fold capillary examination in the same patients during the acute exacerbation and remission periods, it is difficult to claim whether the change of the nail fold capillary bed persists during the remission period. This is the most important limitation of our study. Our study is the first study to evaluate nail fold capillary changes using standard dermoscopic examination, image processing, statistical methods employing texture detection, statistical moment calculation, and k-means classification algorithm in children with FMF.

In conclusion, our study confirmed that abnormalities in the nail fold capillary bed may be seen in children with FMF as previously described in the adult population. Further studies are greatly needed to explore the importance of these findings in FMF.

Ethics Committee Approval: Ethics committee approval was received for this study from the ethics committee of Erciyes University Faculty of Medicine.

Informed Consent: Written informed consent was obtained from patients who participated in this study.

Peer-review: Externally peer-reviewed.

Author Contributions: Conceived and designed the experiments or case: ID, ST, SY, RD. Performed the experiments or case: ID, DT, MB, MEY, AÇ, ABC, KK. Analyzed the data: ID, FB. Wrote the paper: ID, ZG, SY, HP, FB. All authors have read and approved the final manuscript.

Acknowledgment: This study was supported by Erciyes University Research Foundation (TSA-11-3586).

Conflict of Interest: Authors have no conflicts of interest to declare.

Financial Disclosure: The authors declared that this study has received financial support from Erciyes University Scientific Research Center (TSA-11-3586).

REFERENCES

1. Ertan P, Tekin G, Sahin GE, Kasirga E, Taneli F, Kandioğlu AR, Sözeri B. A Case of Henoch-Schönlein Purpura with P369S Mutation in MEFV Gene. *Iran J Pediatr* 2011; 21: 244-8.
2. Girisgen I, Sonmez F, Koseoglu K, Erisen S, Yilmaz D. Polyarteritis nodosa and Henoch-Schönlein purpura nephritis in a child with familial Mediterranean fever: a case report. *Rheumatol Int* 2012; 32: 529-33.
3. Libby P. Inflammation in atherosclerosis. *Nature* 2002; 420:868-74.

4. Benedetto FA, Mallamaci F, Tripepi G, Zoccali C. Prognostic value of ultrasonographic measurement of carotid intima-media thickness in dialysis patients. *J Am Soc Nephrol* 2001; 12: 2458-64.
5. Yamasaki Y, Kodama M, Nishizawa H, Sakamoto K, Matsuhisa M, Kajimoto Y, et al. Carotid intima-media thickness in Japanese type 2 diabetic subjects: predictors of progression and relationship with incident coronary heart disease. *Diabetes Care* 2000; 23: 1310-5.
6. Wendelhag I, Wiklund O, Wikstrand J. Atherosclerotic changes in femoral and carotid arteries in familial hypercholesterolemia: ultrasonographic assessment of intima-media thickness and plaque occurrence. *Arterioscler Thromb* 1993; 13: 1404-11.
7. Manzi S, Meilahn EN, Rairie JE, Conte CG, Medsger TA Jr, Jansen-McWilliams L, et al. Age-specific incidence rates of myocardial infarction and angina in women with systemic lupus erythematosus: comparison with the Framingham Study. *Am J Epidemiol* 1997; 145: 408-15.
8. Sarkis C, Cağlar E, Ugurlu S, Cetinkaya E, Tekin N, Arslan M et al. Nonalcoholic fatty liver disease and familial Mediterranean fever: are they related? *Srp Arh Celok Lek* 2012; 140: 589-94.
9. Corrado A, Carpagnano GE, Gaudio A, Foschino-Barbaro MP, Cantatore FP. Nailfold capillaroscopic findings in systemic sclerosis related lung fibrosis and in idiopathic lung fibrosis. *Joint Bone Spine* 2010; 77: 570-4.
10. Dinc A, Melikoglu M, Korkmaz C, Fresko I, Ozdogan H, Yazici H. Nailfold capillary abnormalities in patients with familial Mediterranean fever. *Clin Exp Rheumatol* 2001; 19: 42-4.
11. Aytakin S, Aydin F, Akpolat T, Senturk N, Turanli AY. Evaluation of nailfold capillaries in familial Mediterranean fever patients. *Clin Rheumatol* 2011; 30: 255-7.
12. Ozturk A, Mazicioglu MM, Hatipoglu N, Budak N, Keskin G, Yazlak Z et al. Reference body mass index curves for Turkish children 6 to 18 years of age. *J Pediatr Endocrinol Metab* 2008; 21: 827-36.
13. Matthews DR, Hosker JP, Rudenski AS, Naylor BA, Treacher DF, Turner RC. Homeostasis model assessment: insulin resistance and beta-cell function from fasting plasma glucose and insulin concentrations in man. *Diabetologia* 1985; 28: 412-9.
14. Atabek E, Eklioglu BS, Akyurek N. Reevaluation of the prevalence of metabolic syndrome in an urban area of Turkey. *J Clin Res Pediatr Endocrinol* 2013; 5: 50-4.
15. R. M. Haralick and L. G. Shapiro. Glossary of computer vision terms. *Pattern Recognition* 1991; 24: 69-93.
16. Linda G. Shapiro and George C. Stockman, *Computer Vision*, Upper Saddle River: Prentice-Hall, 2001.
17. Likas A, Vlassis N, Verbeek JJ, "The global k-means clustering algorithm," *Pattern Recognition* 2003; 36: 451-61.
18. Alsabti K, Ranka S, Singh V, "An efficient k-means clustering algorithm," *Electrical Engineering and Computer Science* 1997; 43.
19. Głowińska-Olszewska B, Bossowski A, Dobreńko E, Hryniewicz A, Konstantynowicz J, Milewski R et al. Subclinical cardiovascular system changes in obese patients with juvenile idiopathic arthritis. *Mediators Inflamm* 2013; 2013: 436702.
20. Soriano A, Verecchia E, Afeltra A, Landolfi R, Manna R. IL-1 β Biological Treatment of Familial Mediterranean Fever. *Clinic Rev Allerg Immunol* 2013 45: 117-30.
21. Demidowich AP, Davis AI, Dedhia N, Yanovski JA. *Med Hypotheses* 2016; 92: 67-73.
22. Latz E, Xiao TS, Stutz A. Activation and regulation of the inflammasomes. *Nat Rev Immunol* 2013; 13: 397.
23. Chae JJ, Cho YH, Lee GS, Cheng J, Liu PP, Feigenbaum L, et al. Gain-of-function pyrin mutations induce NLRP3 protein-independent interleukin-1beta activation and severe auto inflammation in mice. *Immunity* 2011; 34: 755.
24. Ugurlu S, Seyahi E, Cetinkaya F, Ozbakir F, Balci H, Ozdogan H. Intima-media thickening in patients with familial Mediterranean fever. *Rheumatology (Oxford)* 2009; 8: 911-5.
25. Wörnberg J, Marcos A. Low-grade inflammation and the metabolic syndrome in children and adolescents. *Curr Opin Lipidol* 2008; 19: 11-5.
26. Pelajo CF, Lopez-Benitez JM, Miller LC Obesity and disease activity in juvenile idiopathic arthritis. *Pediatr Rheumatol Online J* 2012; 10: 3.
27. Gok F, Dursun I, Gokce I. Does FMF have a property to protect children from obesity?. *Health*, 2010; 2: 268-71.
28. Cortes S, Cutolo M. Capillaroscopic patterns in rheumatic seas. *Acta Rheumatol Port* 2007; 32: 29-36.
29. Cutolo M, Pizzorni C, Secchi ME, Sulli A Capillaroscopy. *Best Pract Res Clin Rheumatol* 2008; 22: 1093-108.
30. Ozen S, Ben-Chetrit E, Bakkaloglu A, Gur H, Tinaztepe K, Calguneri M et al. Polyarteritis nodosa in patients with familial Mediterranean fever (FMF): a concomitant disease or a feature of FMF. *Semin Arthritis Rheum* 2001; 30: 281-8.