



Disseminated Tuberculosis Manifesting as Hepatic Abscess and IVC Thrombosis: A Rare Presentation

CASE REPORT

Deepak Jain¹, Harpreet Singh¹, Kiran B¹, Shaveta Dahiya¹, Promil Jain²

ABSTRACT

Tuberculosis (TB) is the leading cause of morbidity and mortality in developing countries. The involvement of liver the in the form of tubercular liver abscess is a very rare entity in immunocompetent or non-HIV infected individuals. Here we report a case of 32-year old previously healthy male who presented with easy fatigability, decreased appetite, abdominal pain and low-grade fever. Further examination and relevant investigations revealed diagnosis of tubercular liver abscess with pleural effusion and inferior vena cava (IVC) thrombosis. The patient was treated with anti-tubercular drugs and anti-coagulants; he improved symptomatically and recovered without any further complications. Although tubercular liver abscess with IVC thrombosis is a relatively unusual manifestation, timely diagnosis is essential to prevent devastating complications.

Keywords: Tuberculosis, liver abscess, pleural effusion, Inferior vena cava, thrombosis

INTRODUCTION

Tuberculosis (TB) is the most prevalent infectious disease in developing countries. The disease can affect almost every organ system in the body, but it mainly is an infection of lungs. The common presentations of extra pulmonary TB are lymphadenopathy, involvement of the skeletal system, meningitis, pleural or pericardial effusion and miliary TB. Hepatic tuberculosis in the form of tubercular liver abscess is an unusual manifestation but seen commonly in immune-compromised patients. However tubercular liver abscess in immunocompetent and non-HIV infected patients is rarely reported in literature (1). Venous thrombosis is rare vascular complication of TB, which has been scarcely reported (2). It has been previously reported at various sites including the cerebral venous sinuses, inferior vena cava (IVC), hepatic veins and extremities as the deep veins of lower limbs and venous thrombosis attributed to the inflammation and hypercoagulable state. Here, we describe a young immunocompetent male presented with tubercular liver abscess causing IVC thrombosis.

CASE REPORT

We report a case of 32-year old male, who presented with complaints of decreased appetite and easy fatigability for 2 months; he had abdominal pain for 20 days which was dull aching type, localized to the right hypochondrium and epigastrium for 20 days. Patient complained of low grade fever for the past 7 days. He also reported weight loss of around 5kg in the past 1 month. The patient was conscious, haemodynamically stable with blood pressure of 120/70 mmHg, and pulse rate of 88 per minute with regular and of good volume. Patient was febrile (temperature 37.6°C). He had mild pallor and there was no icterus, clubbing, cyanosis, lymphadenopathy or pedal edema. The jugular venous pressure was not raised. On abdominal examination the liver was enlarged, tender, 4 cm below the right costal margin in the mid clavicular line with a span of 17 cm. Respiratory examination revealed decreased chest movements on the right side with a dull note on percussion and decreased air entry in the infra-axillary and infra-scapular region. Other the systemic examinations were normal.

Routine hematological investigations revealed mild anemia with hemoglobin of 9.9g%, WBC of 7000 mm³ with 52% neutrophils and 48% lymphocytes and an elevated erythrocyte sedimentation rate of 75 mm in first hour. A peripheral blood smear examination revealed normocytic normochromic nature suggestive of anemia of chronic disease. The Mantoux test was positive with 12x10 mm induration. Liver function test revealed mildly elevated transaminase levels (Serum glutamic oxalate transaminase/serum glutamic pyruvic transaminase: 68/64 U/L) and elevated serum alkaline phosphatase (206 U/L), bilirubin was 0.6 mg%. The international normalized ratio (INR) was 1.3, however activated partial thromboplastin time (aPTT) was normal. Total serum proteins were decreased (4.8 g%) with an albumin: globulin ratio of 0.8. Renal function tests were normal.

Cite this article as: Jain D, Singh H, Kiran B, Dahiya S, Jain P. Disseminated Tuberculosis Manifesting as Hepatic Abscess and IVC Thrombosis: A Rare Presentation. Erciyes Med J 2018; 40(2): 103-6

¹Department of Medicine, Pt. B.D. Sharma University of Health Sciences, Haryana, India

²Department of Pathology, Pt. B.D. Sharma University of Health Sciences, Haryana, India

Submitted
20.02.2017

Accepted
27.11.2017

Correspondence

Deepak Jain, Department of Medicine, Pt. B.D. Sharma University of Health Sciences, Haryana, India
Phone: +91-9416147887
e-mail: jaindeepakdr@gmail.com

©Copyright 2018
by Erciyes University Faculty of Medicine - Available online at
www.erciyesmedj.com

The Widal test; rapid card test; peripheral blood examination for malaria; and serologies for leptospiral, scrub typhus and dengue were negative. Urine examination was normal. Urine and blood cultures revealed no growth. X-ray chest revealed a blunted right costophrenic angle suggestive of right-sided pleural effusion. (Ultrasound abdomen revealed liver measure approximately 18.4 cm and two hypoechoic lesions suggestive of abscess which were non-aspirable and non-liquefiable. An isoechoic thrombus was noted at IVC near its confluence with the right atrium. A Contrast enhanced computed tomography (CECT) of the abdomen was suggestive of hepatomegaly with liver abscesses, one measuring 93×78×87 mm in the right lobe of liver in the sub diaphragmatic region with no peripheral appreciable liver parenchyma at places and another ill-defined peripherally enhancing lesion sized 62×46×59 mm seen in the segment IV of the liver. Mild ascites was noted. A linear hypodense area was seen along the IVC extending up to the right atrium indicating thrombus. A small splenic infarct was also seen (Figure 1). CECT of the tho-

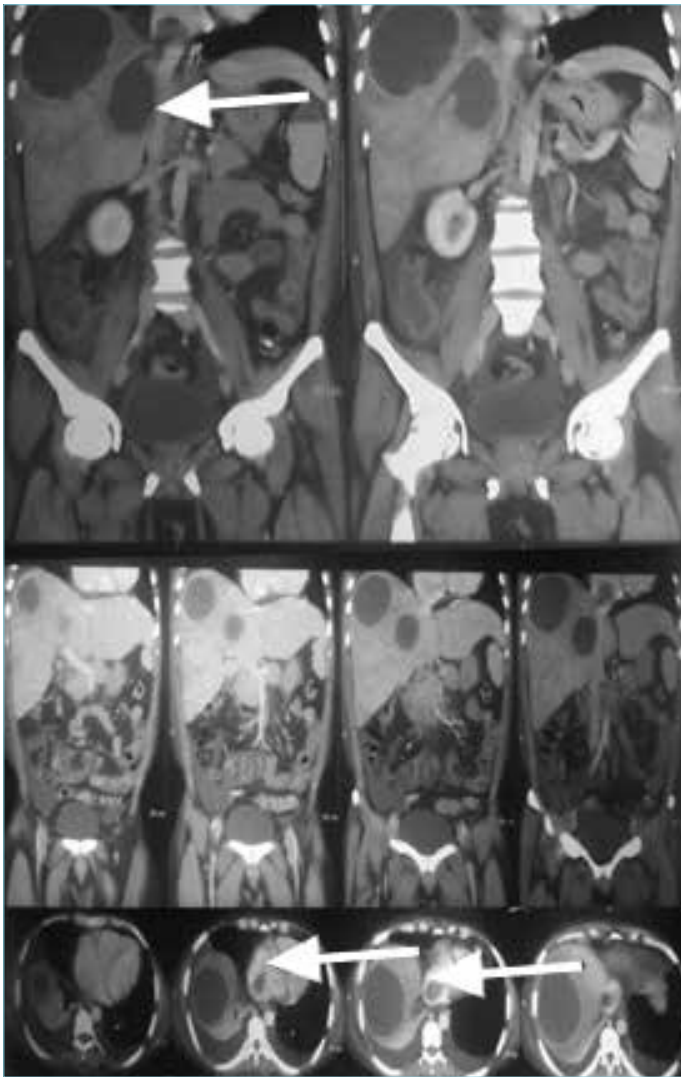


Figure 1. CECT abdomen revealing hepatomegaly with liver abscesses, one abutting IVC, mild ascites and a linear hypodense area was seen along IVC extending up to the right atrium indicating thrombus.

rax revealed right-sided empyema with underlying lung collapse along with a loculated collection in the middle lobe of right lung with mediastinal lymphadenopathy (Figure 2). Echocardiography was suggestive of a mass in the right atrium extending from the IVC likely to be a thrombus with dilated right sided chambers (Figure 3). An aspirate from the liver abscess was negative for trophozoites of ameba or any pyogenic organism. However adenosine deaminase (ADA) was high in the aspirate (427 IU/L) (normal range <30 IU/L) and Mycobacterium tuberculosis DNA was identified by real-time polymerase reaction (PCR) assay. The pleural fluid was exudative with protein of 3.1 gm/dl exhibited a cobweb coagulum, total leukocyte count of 384 cells/cu mm with predominant lymphocytosis and it was positive for ADA (387 IU/L). C-reactive protein was elevated at 5.2 mg/dL. Viral serology for HIV, Hepatitis B and C was negative and general disease laboratory test were negative further anti-nuclear antibody, anti-cardiolipin antibodies and anti-phospholipid antibodies were negative. Other factors for thrombophilia were also ruled out. Serum serology for Entamoeba histolytica by enzyme linked immune sorbent assay was also non-reactive. Patient was started on low molecular heparin and overlapped with warfarin to maintain the INR of 2-3. Anti-tubercular therapy (ATT) with isoniazid, rifampicin, pyrazinamide and ethambutol was given as intensive therapy for 2 months and continued with isoniazid, rifampicin for the 4 months with other supportive measures. Patient improved symptomatically. The size of liver abscess reduced and pleural effusion was completely resolved. The patient is currently under our follow-up and is stable.



Figure 2. CECT thorax revealing right sided effusion with underlying lung collapse with mediastinal lymphadenopathy.

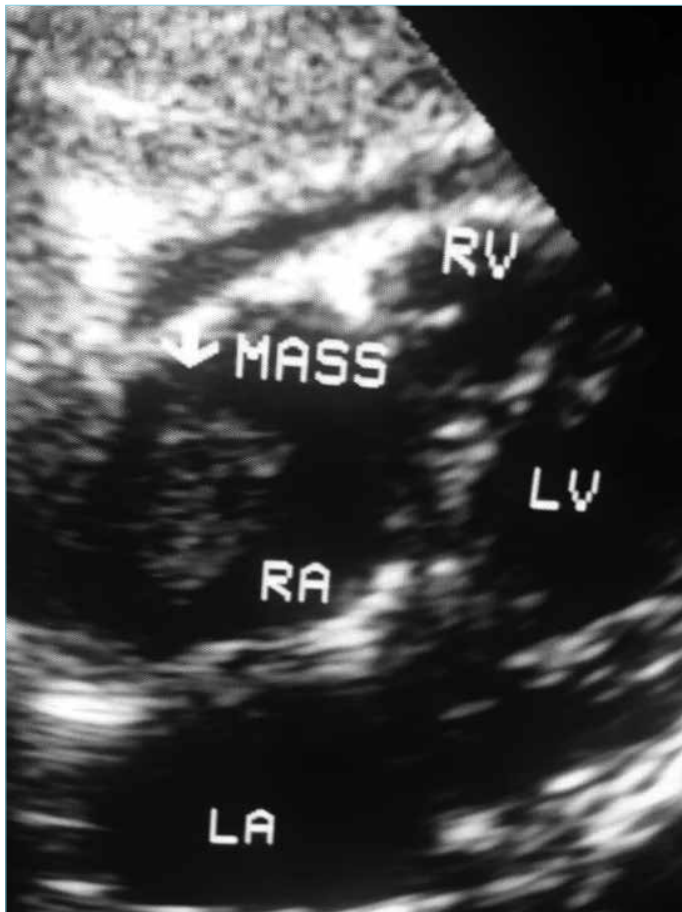

Figure 3. Echocardiography suggestive of a mass in right atrium extending from IVC likely to be a thrombus with dilated right sided chambers

DISCUSSION

Although TB is the most common public health problem particularly in developing countries and worldwide, hepatic TB is not so common and mostly occurs as a part of a disseminated disease. It is seen in around 10%-15% of patients presenting with extra pulmonary TB. Among these patients tubercular liver abscess is reported in only around 0.34% of patients which is secondary to primary lung or gastro-intestinal tuberculosis (3). Hepatic involvement is usually part of disseminated TB and diffuse lympho- hemotogenous spread is the most likely origin of hepatic disease. Levine classified hepatic TB into various forms of presentation such as military TB, primary pulmonary TB with liver involvement, primary liver TB, tuberculoma, and tuberculous cholangitis (4). A low tissue oxygen level render the liver inhospitable for tubercular bacilli; hence the result in low prevalence of tubercular liver abscess. This presentation in an immuno-competent host needs a high level of suspicion for diagnosis (5). It can easily be confused with amebic or pyogenic liver abscess and thus leads to failure of treatment. Symptoms are usually same such as vague right upper quadrant pain, fever and anorexia. However, the diagnosis can be established by detecting *Mycobacterium tubercle* bacilli in the abscess fluid. It is rare to demonstrate acid fast bacilli in hepatic abscess TB. The frequency ranges from 0% to 45%; only 10% of cultures yield positive result which is up to 60% in military TB cases. The most common tech-

nique is DNA quantification by PCR which has sensitivity of 92.4% and high specificity of 98% (6).

Venous thrombosis with TB is also a lesser known complication. Similar to other infections TB can cause thrombosis by various mechanisms such as local invasion, venous compression by adenopathy and tuberculoma or by producing transient hypercoagulable state (7,8). A pro thrombotic state in TB can be attributed to elevated plasma fibrinogen, impaired fibrinolysis, decreased levels of anti-thrombin III and reactive thrombocytosis (7, 8). An increase in the concentration of c-4b binding protein which binds protein c as an acute phase reactant also contributes to the pathophysiology. Peripheral blood mononuclear cells in TB can produce inter-leukin-1 and tumor necrosis factor-alpha and hence causing down-regulation of protein c and protein S during sepsis. There by favoring hypercoagulable state (9). A high level homocystiene and transient rise of factor V and VII have also found to be in patients of disseminated TB hence producing a hypercoagulable state. A transient elevation of anti-cardiolipin antibodies were reported by Manuel Casanova-Roman et al in patient of pulmonary TB and deep vein thrombosis and they hypothesized that two or more anomalies in the anti-coagulation system are necessary for causing venous thrombosis (10). Besides, another factor also plays a major role in the thrombosis i.e, epithelial disruption secondary to mechanical compression by large liver abscess. A generalized inflammatory state also causes endothelitis, which in turn causes stasis and thrombosis in IVC (11).

In our patient the simultaneous presence of pleural effusion, liver abscess and IVC thrombus extending up to the right atrium were documented. The presence of exudative effusion with high level of ADA in the pleural fluid and detection of *Mycobacterium tuberculosis* in the abscess aspirate confirmed the diagnosis of TB. We treated the patient with anti-tubercular drugs along with anti-coagulants. Medical treatment of liver abscess may require ATT for 1 year as thick fibrous tissue around the abscess may prevent anti-tubercular drugs to reach the target. As observed, the hemostatic changes usually improve during the first month of ATT. Hence timely diagnosis and early initiation of ATT is necessary to avoid such complications. However a higher dose of warfarin is needed to achieve therapeutic INR because of the rifampicin effect on cytochrome P450 (12).

CONCLUSION

This case report emphasizes that disseminated TB, particularly hepatic TB can be associated with venous thrombosis at unusual sites such as the IVC. This rare atypical clinical presentation poses a great challenge to the clinical acumen of medical fraternity in developing countries where TB can present in any form. A high degree of suspicion is needed for timely diagnosis and treatment of such cases to avoid further complications.

Ethics Committee Approval: Ethics committee approval was received for this study from the ethics committee of Pt. B D Sharma University of Health Sciences, Rohtak, India.

Informed Consent: Written informed consent was obtained from the patient participated in this study.

Peer-review: Externally peer-reviewed.

Author Contributions: Conceived and designed the experiments or case: HS, DJ. Performed the experiments or case: DJ, PJ. Analyzed the data: TP, YK. Wrote the paper: HS, DJ, KB, SD, PJ. All authors have read and approved the final manuscript.

Conflict of Interest: Authors have no conflicts of interest to declare.

Financial Disclosure: The authors declared that this study has received no financial support.

REFERENCES

1. ShervinShokouhi, Karamollah Toolabi, Shabnam Tehrani, Marjan Hemmatian. Tuberculous liver abscess in an immunocompetent patient: a case report. National Research Institute of Tuberculosis and Lung Disease, Iran. *Tanaffos* 2014; 13(3): 49-51.
2. Ambrosetti M, Ferrarese M, Codecasa L, Besozzi G, Sarassi A, Vighiani P, et al. Incidence of Venous Thromboembolism in Tuberculosis Patients. *Respiration* 2006; 73:396. [\[CrossRef\]](#)
3. Rai R, Tripathi VD, Rangare V, Reddy DS, Patel P. Isolated tubercular liver abscess in an elderly diabetic successfully treated with systemic antitubercular drugs. *J Pak Med Assoc* 2012; 62 (2): 170- 72.
4. Levine C. Primary macronodular hepatic tuberculosis: US and CT appearances. *Gastrointest Radiol* 1990; 15(4):307-9. [\[CrossRef\]](#)
5. Akcay MN, Polat KY, Oren D, Ozturk G. Primary tuberculous liver abscess: a case report and review of literature. *Int J ClinPract*. 2004; 58(6):625-7. [\[CrossRef\]](#)
6. Zakhm F, Lahlou O, Akrim M, Bouklata N, Jaouhari S, SadkiK, et al. Comparison of a DNA Based PCR Approach with Conventional Methods for the Detection of Mycobacterium tuberculosis in Morocco. *Mediterr J Hematol Infect Dis* 2012; 4(1): e2012049. [\[CrossRef\]](#)
7. Robson SC, White NW, Aronson I, Woollgar R, Goodman H, Jacobs P. Acute-phase response and the hypercoagulable state in pulmonary tuberculosis. *Br J Haematol* 1996;93: 943-9. [\[CrossRef\]](#)
8. Turken O, Kunter E, Solmazgul E, Cerrahoglu K, Ilvan A. Hemostatic changes in active pulmonary tuberculosis. *Int J Tuberc Lung Dis* 2002;6(10):927-32.
9. Casanova-Roman Manuel, Rios Jesus, Sanchez-Porto Antonio et al. Deep venous thrombosis associated with pulmonary tuberculosis and transient protein S deficiency. *Scand J Infect Dis* 2002; 34 (5): 393-94. [\[CrossRef\]](#)
10. Casanova-Roman Manuel, Rios Jesus, Sanchez-Porto Antonio et al. Deep venous thrombosis associated with pulmonary tuberculosis and transient protein S deficiency. *Scand J Infect Dis* 2002; 34 (5): 393-4. [\[CrossRef\]](#)
11. Gupta A, Dhua AK, Siddiqui MA, Dympep B, Grover V, Gupta VK, et al. Inferior vena cava thrombosis in a pediatric patient of amebic liver abscess. *JIAPS* 2013;18(1):33-5.
12. Self TH, Mann RB. Interaction of rifampin and warfin. *Chest* 1975; 67: 490-1. [\[CrossRef\]](#)