

**DOI: 10.5152/etd.2017.0072**

**Manuscript Type:** Original Article

**Title:** Comparison Of Sternum Closure Techniques With Sternal Cable And Simple Wire After Open Heart Surgery

**Running Head:** Comparison of sternal cable and simple wire

**Authors:** Rifat Özmen<sup>1</sup>, Ali Tekin<sup>2</sup>

**Institutions:** Kayseri Training And Research Hospital, Kayseri, Turkey<sup>1</sup>

Department of Cardiovascular Surgery, Sağlık Bilimleri University Kayseri Health Practice and Research Center, Kayseri, Turkey<sup>2</sup>

**Address for Correspondence:** Rifat Özmen

**E-mail:** rifatozmen@gmail.com

**Cite this article as:** Özmen R, Tekin A. Comparison Of Sternum Closure Techniques With Sternal Cable And Simple Wire After Open Heart Surgery. Erciyes Med J 2018; DOI: 10.5152/etd.2017.0072

This article has been accepted for publication and undergone full peer review but has not been through the copyediting, typesetting, pagination and proofreading process, which may lead to differences between this version and the Version of Record. Please cite this article as: Özmen R, Tekin A. Comparison Of Sternum Closure Techniques With Sternal Cable And Simple Wire After Open Heart Surgery. Erciyes Med J 2018; DOI: 10.5152/etd.2017.0072

©Copyright 2018 by Erciyes University Faculty of Medicine - Available online at [www.erciyesmedj.com](http://www.erciyesmedj.com)

## ABSTRACT

**Objective:** Median sternotomy is the most commonly used method for open heart surgery. Poor sternal healing after median sternotomy can cause significant increase in morbidity, mortality and prolonged hospital stay. Although several techniques are available for the sternal closure, it is practically limited, and the most common technique is the simple wire technique. There is not enough scientific study on the comparison of the alternative techniques. Therefore, the aim of this study was to compare the follow-up results of the sternotomy closure techniques: Sternal cable and simple wire.

**Methods:** 246 adult patients (141 males, 105 females) who underwent sternotomy closure with sternal cable (99) and simple wire (147) after open heart surgery were examined retrospectively. Patients' postoperative length of hospitalization, sternal dehiscence, local infection, mediastinitis and mortality rates were evaluated. Resternotomy requirement due to sternal decomposition and surgical site infections were evaluated. Statistical comparisons were made in terms of the parameters mentioned above

**Results:** When the groups were compared in terms of age, gender, DM, COPD, CRF and smoking status, there was no statistically significant difference ( $p > 0.05$ ). In comparison with the patients in the simple wire group, the patients' percentage of CABG + MVR (9.09%) was higher ( $p = 0.028$ ) in the sternal cable group. Cross clamp time was longer in the sternal cable group ( $81,24 \pm 31,91$ ) than the simple wire group ( $74,08 \pm 17,67$ ) ( $p = 0.044$ ).

**Conclusion:** Postoperative complications in the sternal cable group were less frequent but statistically not significant in our study. According to our results, sternal cable is effective and can be used as a good alternative to simple wire.

**Keywords:** Sternal dehiscence, closure technique, cardiac surgery, sternal cable, simple wire

This article has been accepted for publication and undergone full peer review but has not been through the copyediting, typesetting, pagination and proofreading process, which may lead to differences between this version and the Version of Record. Please cite this article as: Özmen R, Tekin A. Comparison Of Sternum Closure Techniques With Sternal Cable And Simple Wire After Open Heart Surgery. *Erciyes Med J* 2018; DOI: 10.5152/etd.2017.0072

## INTRODUCTION

Nowadays as the average life span increases, cardiovascular disease rates also increase. Therefore, there is an increase in minimally invasive methods for open heart surgery, and the most commonly used incision is median sternotomy (1, 2). In early 1960s, Julian's median sternotomy was successfully performed in cardiovascular surgery (3). However, the development of sternal dehiscence after median sternotomy can be predicted in the presence of various risk factors. These can be listed as obesity, chronic renal failure (CRF), chronic obstructive pulmonary disease (COPD), smoking, internal mammary artery (IMA) grafting, long cardiopulmonary bypass (CPB) duration, excess blood transfusion, inappropriate fixation methods and osteoporosis (1).

Although the incidence of sternal complications is between 0.5-2.5%, the mortality rate varies between 10-40% in complicated patients. A good sternal fixation is essential to avoid postoperative complications of the sternotomy. Usually, if the closing technique is durable and a good rigidity is provided, successful results can be obtained. Up to the present, many different techniques have been developed and many different materials have been used to achieve the best stability during sternal closure (4-6). However, the studies done to compare these methods are limited, which makes it difficult to evaluate and compare the advantages and disadvantages of these methods (7). The aim of this study was to compare retrospectively the outcomes of the sternal simple wire closure method with the sternal cable method which has recently been proposed as an alternative method.

## MATERIALS and METHODS

### Patients

246 (141 male, 105 female) patients who underwent open-heart surgery between February 2014 and May 2016 in the Kayseri Education and Research Hospital Cardiovascular Surgery Clinic were evaluated retrospectively. Ethical approval for the study was obtained from Ethics Committee of Erciyes University Medicine Faculty (E.C. Number: 2018\233, Date:09.05.2018).

This article has been accepted for publication and undergone full peer review but has not been through the copyediting, typesetting, pagination and proofreading process, which may lead to differences between this version and the Version of Record. Please cite this article as: Özmen R, Tekin A. Comparison Of Sternum Closure Techniques With Sternal Cable And Simple Wire After Open Heart Surgery. Erciyes Med J 2018; DOI: 10.5152/etd.2017.0072

All patients underwent similar preoperative preparations for different cardiac procedures that were using standard median sternotomy (Coronary artery bypass grafting, IMA grafting, Aortic Valve Replacement (AVR), Mitral Valve Replacement (MVR))(Table1).

The SUT (Social Security Institution-Health Application Communique) has been taken into consideration in determining which patients will receive sternal cable. According to the SUT, the criteria like, being over 80 years old, sternal fracture, COPD, bilateral IMA, CFR,  $\geq 30$  BMI etc. were used for sternal cable usage. The sternal cable patients were selected among these patients retrospectively. Sternal simple wire patients were selected among the patients whose sternal closure methods were recorded as simple wire. One of the aims of the study was to determine whether sternal dehiscence developed in both methods during the follow-up period. It is known that osteoporosis may increase the sternal fracture. Therefore, we excluded the patients who had previously undergone sternotomy and had intraoperative sternal bone osteoporosis findings.

After the groups were identified, patients' CRF, COPD, coronary artery disease (CAD), diabetes mellitus (DM) and smoking status were questioned. Then, patients' postoperative length of hospitalization, sternal dehiscence, local infection, mediastinitis and mortality rates were evaluated. Resternotomy requirement due to sternal decomposition and surgical site infections were evaluated.

### **Surgical Procedure**

In 99 patients after median sternotomy, pioneer sternal cable system (RTI Surgical cable®, Part number 400-890) was used. These sternal cables consisted of multi-strand stainless steel and titanium cables. In 147 patients, conventional simple wire method was used for sternal closure. The monofilament 316 LVM Stainless Steel Surgical Cables (made from 100% stainless steel alloy, nickel ratio 0.5-15.0%, chromium ratio 12.0-19.0%) were used for conventional wiring. Multiple 'figure-of-8' wire sutures were used during the sternal closure to provide optimal stabilization in

This article has been accepted for publication and undergone full peer review but has not been through the copyediting, typesetting, pagination and proofreading process, which may lead to differences between this version and the Version of Record. Please cite this article as: Özmen R, Tekin A. Comparison Of Sternum Closure Techniques With Sternal Cable And Simple Wire After Open Heart Surgery. *Erciyes Med J* 2018; DOI: 10.5152/etd.2017.0072

both techniques (Figure 1). The operation durations (CPB and cross clamp time) of both methods were compared (Table 1).

### Statistical Analysis

In summary of the data obtained in this study, categorical variables were presented as number and percent, and continuous variables were presented as mean±standard deviation. The normality test of the numerical variables was tested with the Kolmogorov Smirnov. Independent Samples t test was used for independent two group comparisons. Differences between categorical variables were compared with Pearson Chi-Square test.

For statistical analysis, Jamovi Project (2018), Jamovi (Version 0.9.1.7) [Computer Software]. (Retrieved from <https://www.jamovi.org>) (open source) program was used. Significance level was considered as 0.05 (p value).

### RESULTS

When the groups were compared in terms of age, gender, DM, COPD, CRF and smoking status, there was no statistically significant difference ( $p>0,05$ ) (Table 2).

In comparison with the patients in the simple wire group, the patients in the sternal cable group the percentage of CABG + MVR (9.09%) was higher ( $p=0.028$ ). Cross clamp time was longer in the sternal cable group ( $81.24 \pm 31.91$ ) than the simple wire group ( $74.08 \pm 17.67$ ) ( $p=0.044$ ) (Table 1). In the postoperative 6th week, patients with poor bony healing that was proven in the radiological and physical examinations, were diagnosed as sternal dehiscence. Sternal dehiscence was developed in 3 patients who received sternal cable. Resternotomy and revision were performed to these patients. According to the records, in these patients mediastinitis, local wound infection or leakage was not detected in the sternal region.

According the records, four patients in the sternal simple wire group developed sternal dehiscence, infection and mediastinitis that were requiring sternal re-wiring. Debridement,

This article has been accepted for publication and undergone full peer review but has not been through the copyediting, typesetting, pagination and proofreading process, which may lead to differences between this version and the Version of Record. Please cite this article as: Özmen R, Tekin A. Comparison Of Sternum Closure Techniques With Sternal Cable And Simple Wire After Open Heart Surgery. *Erciyes Med J* 2018; DOI: 10.5152/etd.2017.0072

antibiotherapy and sternal rewiring were performed on this patient. The average hospitalization period for these patients was 4-6 weeks. In sternal cable group, no infection, mediastinitis or sternal re-wiring were recorded. In the sternal simple wire group, in three patients local wound infection was developed due to wire reaction. Under local anesthesia, local wound site debridement and wire extraction were performed on this patient. The average hospitalization period for these patients was 3-5 days.

## DISCUSSION

With the increase in the average life span, there is also an increase in cardiac diseases. Though there is an increase in minimally invasive methods in open heart surgery, the most commonly used incision method is median sternotomies (1, 2). As a result of the complications that could occur in the superficial or deep sternal areas in the region and led to a significant cost increase, it has come across with both increased mortality and morbidity. Although simple wire method is the most commonly used sternum closure technique today, new methods can be used for sternal reconstruction instead of conventional simple wire. In complicated cases such as multiple sternal fractures, infections, postoperative dehiscence, reoperations or osteoporosis another technique might be useful (1, 9-13). In our study, sternal dehiscence was developed in both groups and re-wiring was performed with the sternal cable for all these patients. In the sternal cable group, no infection was detected in patients who developed dehiscence, but in the simple wire group all patients had infections. Factors such as obesity, osteoporosis, non-midline sternotomy, peripheral artery disease, smoking, inadequate bone fixation contribute to the development of sternal dehiscence (14). Nevertheless, when the groups were compared in terms of age, gender, DM, COPD, CRF and smoking status, there was no statistically significant difference in our study.

Tunçay et al. evaluated six uninfected sternal dehiscence where sternal reconstruction was performed with sternal clips. They reported that sufficient bone healing occurred and early postoperative pain decreased (1). Comparably in our study, re-wiring was performed with sternal

This article has been accepted for publication and undergone full peer review but has not been through the copyediting, typesetting, pagination and proofreading process, which may lead to differences between this version and the Version of Record. Please cite this article as: Özmen R, Tekin A. Comparison Of Sternum Closure Techniques With Sternal Cable And Simple Wire After Open Heart Surgery. *Erciyes Med J* 2018; DOI: 10.5152/etd.2017.0072

cable in patients who developed sternal dehiscence in both groups and success in treatment was achieved.

Melly et al. aimed to compare the sternal cable and sternal wire techniques in terms of infection and other infectious events. They indicated there was no statistically significant difference when comparing cable with wire, in terms of sternal infection. The postoperative complications were found similar in both sternal closure methods. In our study, while no infection or wire reaction was observed in sternal cable group, both infection and wire reaction were observed in simple wire group. Melly et al. (3) also suggested that the cable technique was fast, easy to use, reliable and safe. On the contrary, cross clamp time was found longer in the sternal cable group in our study. However, this may be due to the fact that the percentage of patients who underwent CBPG+MVR was higher in the sternal cable group in our study.

Grapow et al. aimed to evaluate the short time results of the cable-tie based closure system. In their study, sternal instability was not observed during postoperative 30 days. They suggested that the short time results of cable-tie based closure system was satisfactory and it could be used safely and effectively. They also stated that cable-tie based closure system was fast, easy to use and could be an alternative for traditional wire closure (9).

In this study, however, no comparison was made between simple wire and sternal cable

In a very similar to our study, Oh et al. (7) and Dunne et al. (8) aimed to compare the effects of sternal cable and sternal wire techniques that performed for sternal closure after cardiac surgery. Oh et al. (7) compared the surgical outcomes of the multifilament cable with multifilament stainless steel wire in 1354 patients' retrospectively examined data. They did not observe significant differences between the two groups in terms of mortality, major wound complications requiring reoperation, minor wound complications or mediastinitis. They indicated that multifilament cable group had fewer sternal bleedings but it was not statistically significant (7). Dunne et al. (8) suggested that the sternal cable method seems to help early extubation after cardiac surgeries, but it does not reduce the rate of deep sternal infections.

This article has been accepted for publication and undergone full peer review but has not been through the copyediting, typesetting, pagination and proofreading process, which may lead to differences between this version and the Version of Record. Please cite this article as: Özmen R, Tekin A. Comparison Of Sternum Closure Techniques With Sternal Cable And Simple Wire After Open Heart Surgery. *Erciyes Med J* 2018; DOI: 10.5152/etd.2017.0072

In these two studies, which are similar to ours, the superiority of the sternal cable to the simple wire was not clearly demonstrated. Similar results were obtained in our study. Although, various complications (sternal dehiscence, sternal bleeding, infections, prolonged extubation time etc.) seems less in the sternal cable technique according to these studies including ours, no statistical significance was shown.

However, it was stated in all studies that the sternal cable technique is as simple, reliable and effective as the simple wire method and could be used as an alternative method.

There was no statistical difference between the groups in terms of demographic characteristics in our study. This suggests that the two groups were proper for comparison. However, our study has limitations such as being retrospective and not being able to randomized.

## **CONCLUSION**

In our study, postoperative complications in the sternal cable group were less frequent but not statistically significant. According to our results, sternal cable is effective and can be used as a good alternative to simple wire.

In order to make this comparison more accurate, there is a need for randomized studies with more parameters and more patients.

This article has been accepted for publication and undergone full peer review but has not been through the copyediting, typesetting, pagination and proofreading process, which may lead to differences between this version and the Version of Record. Please cite this article as: Özmen R, Tekin A. Comparison Of Sternum Closure Techniques With Sternal Cable And Simple Wire After Open Heart Surgery. Erciyes Med J 2018; DOI: 10.5152/etd.2017.0072



## REFERENCES

1. Tunçay A, Akçalı Y, Özmen R, Gazioğlu Ö, Serhatlıoğlu F. Vitalitec International, The Sternal Closure Device: A novel closure technique for sternal dehiscence. *Journal of Clinical and Experimental Investigations* 2014; 5: 534-538.
2. Okutan H, Yavuz T, Uluhan V, Tenekeci C, Öcal A, İbrişim E, et al. The experience of a new sternal closure technique after open heart surgery in elderly patients. *Turkish Journal of Geriatrics* 2001; 4:55-58.
3. Melly L, Gahl B, Meinke R, Ruetra F, Matta P, Reuthebuch O, Eckstein SF, Garapova M. A new cable-tie based sternal closure device: infection considerations. *Interactive Cardiovascular and Thoracic Surgery*, 17(2013)219-224
4. Eğileten ZB, Kahraman D, Eryılmaz S, Uysal A, Özyurda Ü. Prophylactic combination of robotic method and the figure of 8 in patients with risk factors for sternal complications. *Turkiye Klinikleri Journal of Medical Sciences* 2006; 26:51-55.
5. Orhan SN, Öyazıcıoğlu HM, Çolak A. A biomedical study of 4 different sternum closure techniques under different deformation modes. *Interactive Cardiovascular and Thoracic Surgery* 25 (2017) 750–756
6. Dieselman JC. Comparison of alternative rigid sternal fixation techniques. MSc. Thesis, Worcester Polytechnic Institute, Worcester, Massachusetts; 2011
7. Oh YN, Ha KJ, Kim JB, Jung SH, Choo SJ, Chung CH et al. Multifilament Cable Wire versus Conventional Wire for Sternal Closure in Patients Undergoing Major Cardiac Surgery. *Korean J Thorac Cardiovasc Surg* 2015; 48:265-271

This article has been accepted for publication and undergone full peer review but has not been through the copyediting, typesetting, pagination and proofreading process, which may lead to differences between this version and the Version of Record. Please cite this article as: Özmen R, Tekin A. Comparison Of Sternum Closure Techniques With Sternal Cable And Simple Wire After Open Heart Surgery. *Erciyes Med J* 2018; DOI: 10.5152/etd.2017.0072

8. Dunne B, Murphy M, Skiba R, Wang X, Ho K, Larbalestier R ve ark. Sternal cables are not superior to traditional sternal wiring for preventing deep sternal wound infection. *Interact Cardio Vasc Thorac Surg* 2016; 22:594–8.
9. Grapow M, Melly L, Eckstein F, Reuthebuch O. A new cable-tie based sternal closure system: description of the device, technique of implantation and first clinical evaluation. *Journal of Cardiothoracic Surgery* 2012, 7:59
10. Voss B, Bauernschmitt R, Will A, Kröss R, Brockmann G, Libera P ve ark. Sternal reconstruction with titanium plates in complicated sternal dehiscence. *Eur J Cardio thorac Surg* 2008; 34:139-145.
11. Lazar HL, Vander Salm T, Engelman R, Orgill D, Gordon S. Prevention and management of sternal wound infection. *J ThoracCardiovasc Surg.* 2016; 152:962–72.
12. Olbrecht VA, Barreiro CJ, Bonde PN, Williams JA, Baumgartner WA, Gott VL et al. Clinical outcomes of noninfectious sternal dehiscence after median sternotomy. *Ann ThoracSurg*2006;82: 902-7.
13. Huh J, Bakaeen F, Chu D, Wall MJ. Transverse sternal plating in secondary sternal reconstruction. *J Thorac Cardiovasc Surg* 2008; 136:1476-1480.
14. Kaul P. Sternal reconstruction after poststernotomy mediastinitis. *Journal of Cardiothoracic Surgery* (2017) 12: 94.

This article has been accepted for publication and undergone full peer review but has not been through the copyediting, typesetting, pagination and proofreading process, which may lead to differences between this version and the Version of Record. Please cite this article as: Özmen R, Tekin A. Comparison Of Sternum Closure Techniques With Sternal Cable And Simple Wire After Open Heart Surgery. *Erciyes Med J* 2018; DOI: 10.5152/etd.2017.0072

**Table 1.** Surgical procedures and the duration of the operations.

	Sternal Cable Group	Simple Wire Group	p-values
IMA grafting	84 (84,85)	132 (89,8)	
CABG	87 (87,88)	138 (93,88)	
AVR	3 (3,03)	3 (2,04)	
CABG+MVR	9 (9,09)	<b>3 (2,04)</b>	<b>0,028</b>
MVR	0 (0)	3 (2,04)	
CPB time (min)	101,82±42,75	96,45±32,72	0,291
XCL time (min)	81,24±31,91	74,08±17,67	0,044

Categorical variables presented as number (%) and continuous variables presented as mean±standard deviation

IMA: Internal mamarian artery; CABG: coronary artery bypass grafting; AVR: aortic valve replacement; MVR: mitral valve replacement; CBP: cardiopulmonary bypass; XCL: cross-clamp

This article has been accepted for publication and undergone full peer review but has not been through the copyediting, typesetting, pagination and proofreading process, which may lead to differences between this version and the Version of Record. Please cite this article as: Özmen R, Tekin A. Comparison Of Sternum Closure Techniques With Sternal Cable And Simple Wire After Open Heart Surgery. *Erciyes Med J* 2018; DOI: 10.5152/etd.2017.0072

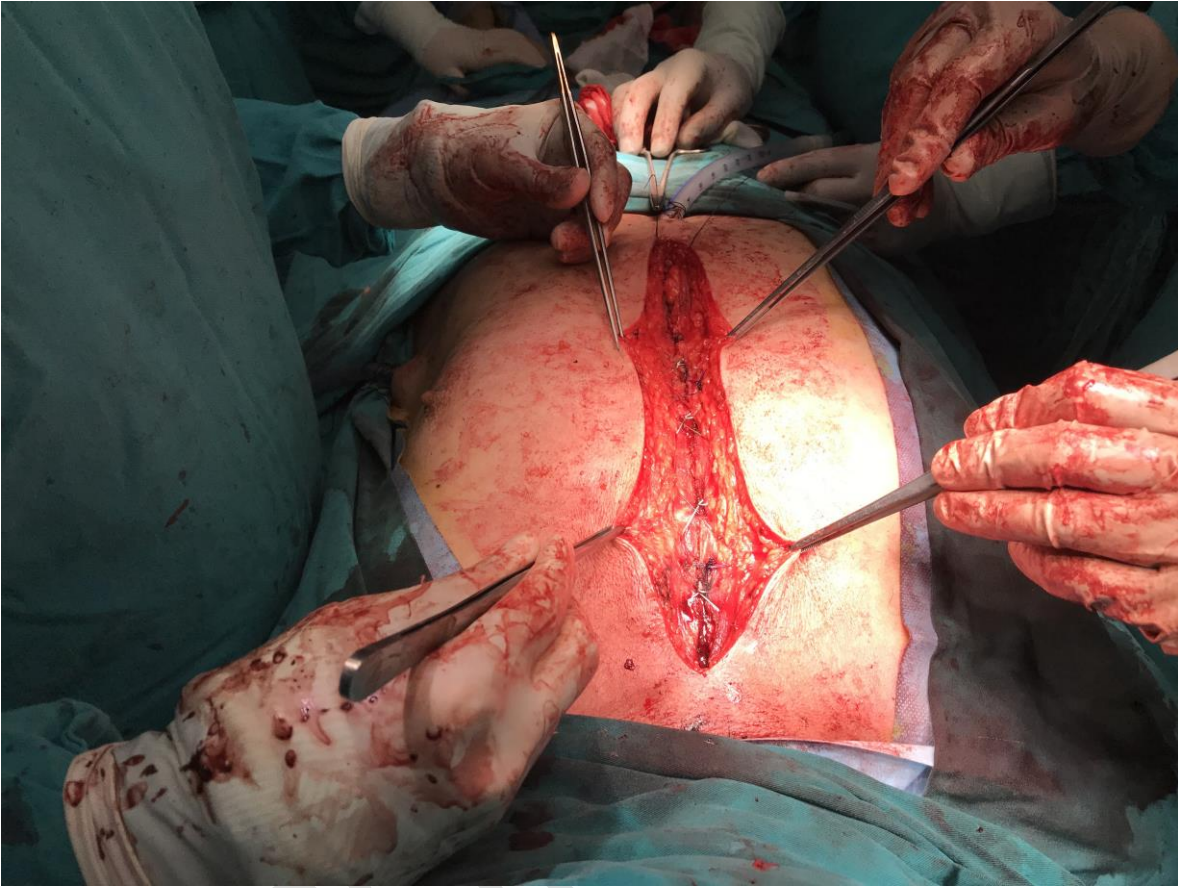
**Table 2.** Baseline demographic characteristics of the patients

Demographic Characteristics	Sternal Cable Group	Simple Wire Group	p values
Age (Year±Sd)	59,02±7,97	59,8±7,25	0,430
Gender (Female/Male)	39 (39,39)/60(60,61)	66 (44,9)/81(55,1)	0,392
CRF	3(3,03)	5 (3,4)	0,371
COPD	39 (39,39)	54 (36,73)	0,673
DM	69 (69,7)	96 (65,31)	0,472
Smoking	45 (45,45)	57 (38,78)	0,297

Categorical variables presented as number (%) and continuous variables presented as mean±standard deviation

CRF: chronic renal failure; COPD: chronic obstructive pulmonary disease; DM: diabetes mellitus

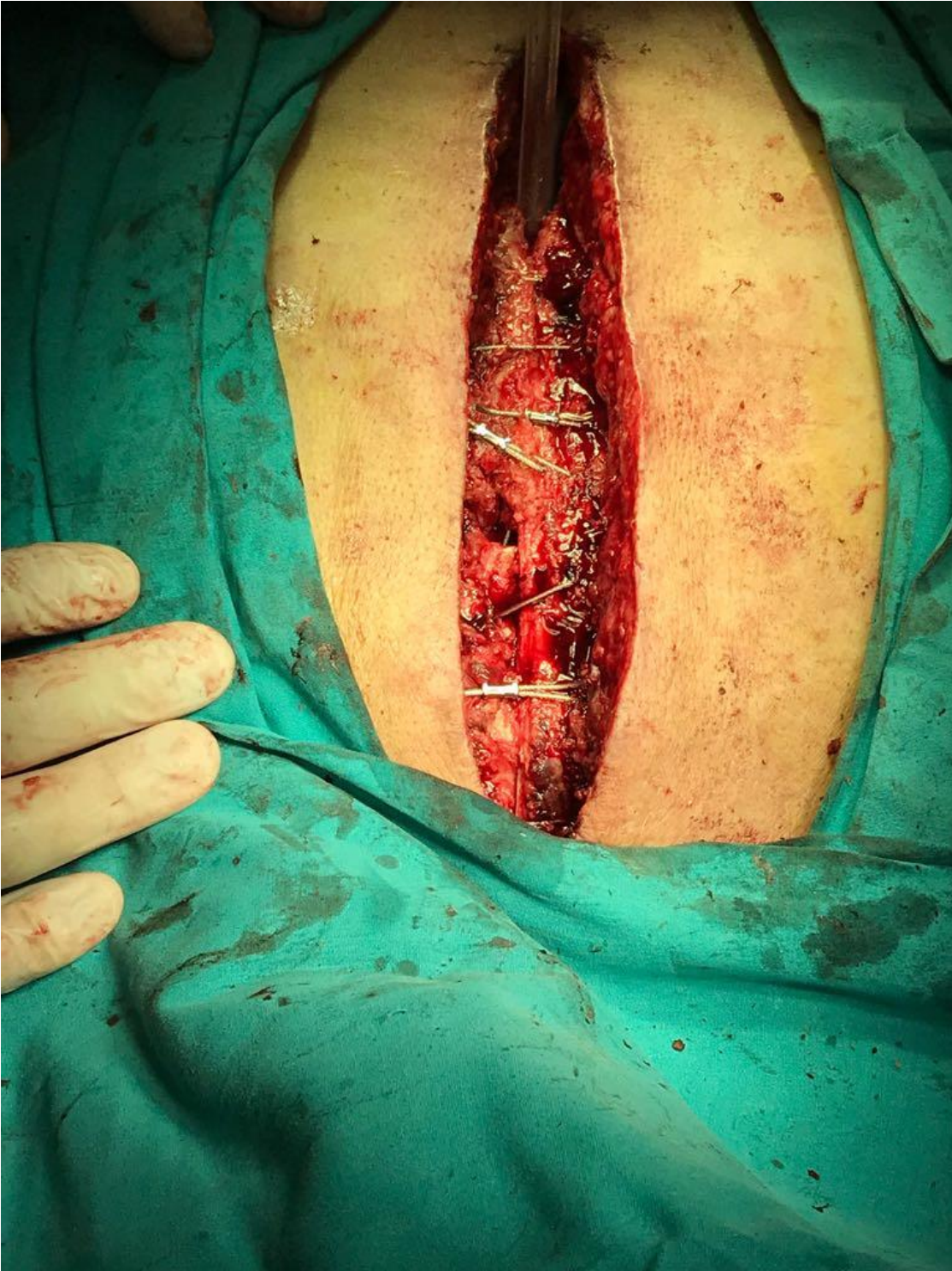This article has been accepted for publication and undergone full peer review but has not been through the copyediting, typesetting, pagination and proofreading process, which may lead to differences between this version and the Version of Record. Please cite this article as: Özmen R, Tekin A. Comparison Of Sternum Closure Techniques With Sternal Cable And Simple Wire After Open Heart Surgery. Erciyes Med J 2018; DOI: 10.5152/etd.2017.0072



**Figure 1**

This article has been accepted for publication and undergone full peer review but has not been through the copyediting, typesetting, pagination and proofreading process, which may lead to differences between this version and the Version of Record. Please cite this article as: Özmen R, Tekin A. Comparison Of Sternum Closure Techniques With Sternal Cable And Simple Wire After Open Heart Surgery. Erciyes Med J 2018; DOI: 10.5152/etd.2017.0072

©Copyright 2018 by Erciyes University Faculty of Medicine - Available online at [www.erciyesmedj.com](http://www.erciyesmedj.com)



This article has been accepted for publication and undergone full peer review but has not been through the copyediting, typesetting, pagination and proofreading process, which may lead to differences between this version and the Version of Record. Please cite this article as: Özmen R, Tekin A. Comparison Of Sternum Closure Techniques With Sternal Cable And Simple Wire After Open Heart Surgery. Erciyes Med J 2018; DOI: 10.5152/etd.2017.0072

©Copyright 2018 by Erciyes University Faculty of Medicine - Available online at [www.erciyesmedj.com](http://www.erciyesmedj.com)