



# Beneficial Effects of Quercetin on the Zone of Stasis in an Experimental Burn Model

ORIGINAL  
ARTICLE

Erkan Orhan<sup>1</sup>, Ertan Şahin<sup>2</sup>, Melike Sapmaz Metin<sup>3</sup>, Yeter Tarladaçalışır<sup>3</sup>

ABSTRACT

**Objective:** In burn injury, the zone of stasis determines the width and depth of the necrosis. Our aim is to show the effectiveness of quercetin on the viability within the zone of stasis in burns of rats.

**Materials and Methods:** Forty-eight rats were divided into three groups. The rats in Group 1 (control group) were only applied the comb burn model; the rats in Group 2 (post-burn group) were administered 50 mg/kg of quercetin intraperitoneally, every day after the burn procedure until euthanasia; and the rats in Group 3 (pre-burn group) were administered 50 mg/kg of quercetin intraperitoneally, every day for 7 days before and after the burn procedure until euthanasia.

**Results:** The living tissue calculated was 85.41% ( $\pm 14.06$ ) in Group 3, 40.37% ( $\pm 9.75$ ) in Group 2, and 16.81% ( $\pm 9.4$ ) in Group 1. The level of apoptosis was 30.0 ( $\pm 10.8$ ) in Group 3, 33.8 ( $\pm 08.7$ ) in Group 2, and 37.4 ( $\pm 11.5$ ) in Group 1. The level of autophagy was 49.50 ( $\pm 8.58$ ) in Group 3, 27.17 ( $\pm 5.53$ ) in Group 2, and 21.00 ( $\pm 5.66$ ) in Group 1. All the differences between the groups were statistically significant ( $p < 0.01$ ).

**Conclusion:** Quercetin reduces apoptosis and increases autophagy, thereby increasing tissue viability in the zone of stasis of burn injury.

**Keywords:** Zone of stasis, quercetin, apoptosis, autophagy

**Cite this article as:**

Orhan E, Şahin E, Sapmaz-Metin M, Topçu-Tarladaçalışır Y. Beneficial effects of Quercetin on the zone of stasis in an experimental burn model. Erciyes Med J 2018; DOI: 10.5152/etd.2017.0164

## INTRODUCTION

In burn trauma, the affected tissue may become deeper and wider due to the continuing wound necrosis even after thermal injury, and the amount of damaged tissue may increase (1). Tissues affected by thermal injury can be divided into 3 zones according to the severity of damage and the blood flow changes. The central area in which the tissue is irreversibly damaged and coagulation necrosis occurs is called the zone of coagulation. The area surrounding this zone, where the posttraumatic tissues are indirectly damaged, is called the zone of stasis. The outermost region, which has no direct damage after trauma, however, has an increased blood flow and inflammatory response to trauma, and it is called the zone of hyperemia (2). Although the tissues in the zone of stasis maintain survival immediately after the burn injury, cells in these tissues can die within the following 48 hours because of a decreased blood flow due to edema, prolonged inflammation, formation of free oxygen radicals, accumulation of cytotoxic cytokines, and hypercoagulability. This tissue death is in the form of necrosis and apoptosis (1). To prevent the tissue death in the zone of stasis is one of the basic aims of burn treatment (2, 3).

Several experimental studies have been carried out using anti-thrombotic, anticoagulant, anti-inflammatory, and antioxidant agents to stop cell death in tissues in the zone of stasis. Although certain achievements have been made, however, none of the drugs are used in clinical practice (4-6).

Quercetin (3,3',4',5,7-pentahydroxyflavone) is a flavonol type flavonoid. It is found in many fruits and vegetables, mainly in citrus fruits, onions, and broccoli, and it is the most prominent flavonoid in regular diet (7). Several studies have shown that quercetin has an antioxidant, anti-inflammatory, antiapoptotic, and autophagy-inducing activity (8).

The present hypothesis is that quercetin can increase the viability of the tissues within the zone of stasis of a burn due to its antiapoptotic and autophagy-inducing properties. Our aim in this study is to show the effectiveness of quercetin on the viability within the zone of stasis of burns in rats via pre-burn and post-burn treatment.

## MATERIALS and METHODS

The study was approved by the Experimental Animals Local Ethics Committee of T. University and was carried out in the T. University's Experimental Animal Production and Research Laboratory. Forty-eight Wistar albino female

<sup>1</sup>Department of Plastic Surgery, Namik Kemal University, Faculty of Medicine, Tekirdağ, Turkey

<sup>2</sup>Department of Nuclear Medicine, Gaziantep University, Faculty of Medicine, Gaziantep, Turkey

<sup>3</sup>Department of Histology and Embryology, Trakya University, Faculty of Medicine, Edirne, Turkey

Submitted  
23.12.2017

Accepted  
18.05.2018

Available Online Date  
03.09.2018

**Correspondence**

Erkan Orhan  
Department of Plastic Surgery,  
Namik Kemal University,  
Faculty of Medicine, Tekirdağ,  
Turkey  
Phone: +90 2822505500  
e.mail:  
erohan@yahoo.com

rats, weighing 250-350 g, raised in the T. University Experimental Animal Production and Research Laboratory, were used for the study. The rats were housed in appropriate cages, at an average temperature of 24 °C, and 12 hours of darkness and 12 hours of light were provided.

All surgical procedures were performed by the same surgeon under sterile conditions, with 10% ketamine HCl (50 mg/kg, Alfamine®, intramuscularly) and xylazine HCl (2.5 mg/kg, Rompun®, intramuscularly) anesthesia. The animals were kept in separate cages to prevent the rats from harming each other in the post-surgical period. All rats were fed a standard rat diet and no water or feed restriction was applied.

The rats were divided into three groups, and each group was divided into two subgroups; by doing so, six groups were formed, with eight rats per group. The number of subjects in each subgroup was determined so as to use the least number of animals necessary for statistical analysis, as referenced in previous studies (9).

The rats in Group 1 (control group) were administered 1 ml of dimethylsulfoxide (DMSO), intraperitoneally, every day for 7 days before and after the burn procedure, until euthanasia was performed.

The rats in Group 2 (post-burn group) were administered 1 ml of DMSO, intraperitoneally, every day for 7 days, before the burn procedure and 50 mg/kg of quercetin in 1 ml of DMSO, intraperitoneally, every day after the burn procedure until euthanasia was performed (10).

The rats in Group 3 (pre-burn group) were administered 50 mg/kg of quercetin in 1 ml of DMSO, intraperitoneally, every day for 7 days before and after the burn procedure until euthanasia was performed (10).

Each group was divided into two subgroups: a and b. Euthanasia was performed on the animals in the a subgroups (Group 1a, Group 2a, Group 3a) by administering a high dose of an anesthetic agent 24 hours after the burn procedure. In those subgroups, the zone of stasis tissue was excised and stored in 10% formalin at 4°C, and then the tissues were used to determine apoptosis and the autophagy levels by immunohistochemical examinations.

Euthanasia was performed on the animals in the b subgroups (Group 1b, Group 2b, Group 3b) by administering a high dose of an anesthetic agent 7 days after the burn procedure. In those subgroups, scintigraphic and macroscopic examinations were performed first. The zone of stasis tissues were then harvested and stored in 10% formalin at 4°C, and then these tissues were used to determine proliferation levels by immunohistochemical examinations.

### Burn Procedure

After anesthesia with ketamine and xylazine, the dorsum of the animals was shaved. After the appropriate antiseptic application, burns were created on the dorsum of each animal using a custom-made steel comb with four rectangular rows (20x10 mm) and three interspaces (20x5 mm) weighing 150 gr pre-heated in boiling water for 15 minutes and applied without pressure for 20 seconds. This resulted in four rectangular 10x20 mm full-thickness burns

separated by three 5x10 mm unburned interspaces representing the zone of stasis, according to the comb burn model defined by Regas and Ehrlich (11).

### Macroscopic Examination

Photographs of all the animals were taken from the same distance (60 cm) with a Sony DSC-F828 camera (Sony Corporation, Tokyo, Japan). The living and necrotic areas were calculated by using the program Adobe Photoshop CS 5 (Adobe Systems, Inc., San Jose, CA). The zones of stasis and the living tissue areas were marked on the software, the sizes were noted in pixels, and then the percentage was calculated (12).

### Scintigraphic Examination

Two rats were randomly selected from each of Groups 1b, 2b, and 3b. These rats were administered 2 cc of 111 MBq (3 mCi) technetium-99m methoxyisobutylisonitrile (<sup>99</sup>Tc<sup>m</sup>-MIBI) intravenously, 7 days post-burn, after being given anesthesia with ketamine and xylazine, and then, they were euthanized by a high dose of anesthesia administered after 30 minutes. The burned areas were excised by the inclusion of 2 cm of normal skin and its panniculus carnosus surrounding the area. One hour after the injection of <sup>99</sup>Tc<sup>m</sup>-MIBI, scintigraphic images of the specimens were taken using a gamma camera. On the images, the relatively linear increasing activities between the zones of burn were evaluated as vital areas, and they were proportioned by counting the number of pixels.

Terminal Deoxynucleotidyl (TUNEL) Assay Apoptosis was calculated in tissue samples taken from the zone of stasis of the control and both experimental groups, on the 24th hour. To detect apoptosis, a terminal deoxynucleotidyl transferase dUTP nick end labeling (TUNEL) assay was performed using an in-situ apoptosis detection kit (ApopTag Plus Peroxidase in Situ Apoptosis Detection Kit; S7101-KIT, EMD Millipore) by following the manufacturer's instructions. Slides were examined under high magnification with a light microscope (400x). The TUNEL positive cells were identified by intense brown nuclear staining and were evaluated in 10 randomly selected areas per section in the zone of stasis. Data were expressed as the average of cell numbers per sample.

### Immunohistochemical Examination

Immunohistochemical examination was calculated in tissue samples taken from the zone of stasis of the control and both experimental groups, on the 24th hour. Formalin-fixed and paraffin-embedded skin tissues were sectioned at 5µm. For the immunohistochemical process, the sections were deparaffinized and rehydrated, and a heat-mediated antigen retrieval was performed. The sections were then exposed to 3% hydrogen peroxide for 10 minutes. After overnight incubation with primary antibodies, proliferating cell nuclear antigen (PCNA) 1:20,000 (Cell Signaling, USA); anti-beclin; 1:100 (Novus, USA); and then peroxidase-conjugated secondary antibodies were applied. The immunoreactivity was visualized with diaminobenzidine (Vector Laboratories), and counterstaining was performed with hematoxylin.

The PCNA positive cells and Beclin 1-positive cells were evaluated in 10 randomly selected areas under a microscope at high magnification (400x). Data were expressed as the average of cell numbers per sample.

### Statistical Analysis

The Statistical Package for the Social Sciences version 17.0 software (SPSS Inc.; Chicago, IL, USA) program was used for data analysis. Whether the distribution of continuous variables was normal or not was assessed by the Shapiro–Wilk test. The Levene test was used to evaluate the homogeneity of variances. Data were expressed as mean±standard deviation or median (25%-75%). If the variables were normally distributed, the differences between the groups were determined using the Kruskal Wallis test; if not, the one-way analysis of variance (ANOVA) test was used. If the p-value was statistically significant, according to the one-way ANOVA, the post-hoc Tukey Honestly Significant Difference (HSD) test was performed to show which group was more significant. The Student's t or Mann–Whitney U tests were used to determine whether there was a statistically significant difference between the groups euthanized at the 24th hour and the 7th day, within the same control or treatment group. A p-value of less than 0.05 was considered statistically significant.

## RESULTS

### Macroscopic Examination

The mean value of the living tissue in the zone of stasis in Group 1b (control group) was estimated as 16.81% ( $\pm 9.4$ ), in Group 2b (post-burn treatment group) as 40.37% ( $\pm 9.75$ ), and in Group 3b (pre-burn treatment group) as 85.41% ( $\pm 14.06$ ). When the groups were compared statistically, the amount of the living tissue in Group 3b was found to be statistically higher than that of Group 1b and Group 2b ( $p=0.002$  and  $p<0.001$ ), and the amount of living tissue in Group 2b was higher than that of Group 1b ( $p<0.001$ ) (Table 1; Figures 1, 2).

### Scintigraphic Evaluation

During the study, it was not possible to scan all experimental animals due to technical limitations; therefore, only 2 subjects from each group were scanned. The gamma counts per pixel (cpp) of the rats that were scanned from Group 3b (pre-burn treatment group) were measured as 7975.72 cpp and 8165.61 cpp; from Group 2b (post-burn treatment group) as 7240.55 cpp and 7080.60 cpp; and from Group 1b (control group) as 6110.95 cpp and 6350.45 cpp. A statistical comparison was not performed due to the low number of samples (Figure 3).

### Determination of Apoptosis

Apoptotic cells were detected in the hair follicular epithelium, primarily in the surface epithelium. The average amount of apoptosis was detected as 37.4 ( $\pm 11.5$ ) in Group 1a (control group); 33.8 ( $\pm 8.7$ ) in Group 2a (post-burn treatment group); and 30 ( $\pm 10.8$ ) in Group 3a, (pre-burn treatment group). When the statistical analysis was performed, the amount of apoptosis in Group 3a was found to be statistically lower than that of Group 1a and Group 2a ( $p<0.01$ ), and the amount of apoptosis in Group 2a was found to be statistically lower than that of Group 1a ( $p<0.01$ ) (Table 2, Figure 4).

### Determination of Autophagy

Beclin-positive cells, which indicate the presence of autophagy, were distinguished by their dark-brown-stained cytoplasm 24 hours after burn injury in the zone of stasis and especially in the deep dermis. The mean amount of autophagy detected in Group

**Table 1.** The mean amount of living tissue and the mean PCNA levels in the zone of stasis on the post-burn Day 7

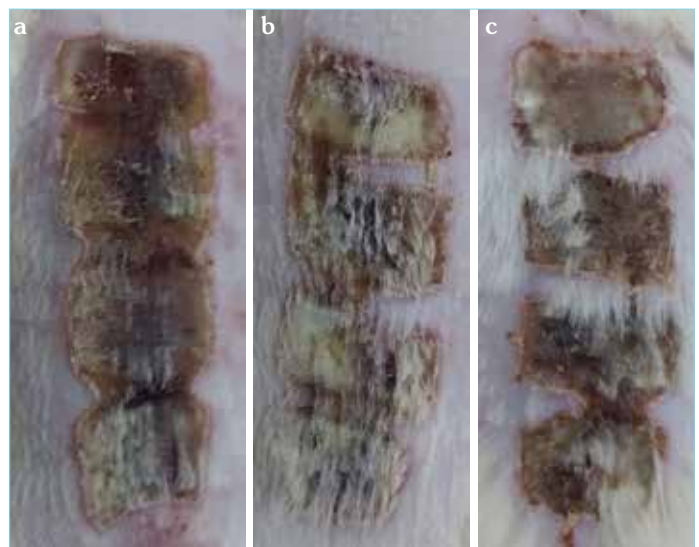
	Amount of Living Tissue (%) <sup>†</sup>	PCNA <sup>††</sup>
Group 1	16.81 $\pm$ 9.48 <sup>a,b</sup>	30.00 $\pm$ 10.80 <sup>b,c</sup>
Group 2	40.37 $\pm$ 9.75 <sup>a,c</sup>	33.80 $\pm$ 8.70 <sup>c</sup>
Group 3	85.41 $\pm$ 14.06 <sup>b,c</sup>	54.40 $\pm$ 3.65 <sup>b,c</sup>
p	<0.001 <sup>†</sup>	<0.05 <sup>††</sup>

PCNA: proliferating cell nuclear antigen  
<sup>†</sup>One-way ANOVA, <sup>a</sup>: Group 1 vs Group 2 ( $p<0.05$ ), <sup>b</sup>: Group 1 vs Group 3 ( $p<0.01$ ), <sup>c</sup>: Group 2 vs Group 3 ( $p<0.001$ ).  
<sup>††</sup>One-way ANOVA, <sup>a</sup>: Group 1 vs Group 2 ( $p=0.764$ ), <sup>b</sup>: Group 1 vs Group 3 ( $p=0.019$ ), <sup>c</sup>: Group 2 vs Group 3 ( $p=0.008$ ).

**Table 2.** The mean apoptosis and autophagy levels in the zone of stasis at the post-burn 24th hour

	Apoptosis	Autophagy
Group 1	37.4 $\pm$ 11.5 <sup>a</sup>	21.00 $\pm$ 5.66 <sup>a</sup>
Group 2	33.8 $\pm$ 8.7 <sup>b</sup>	27.17 $\pm$ 5.53 <sup>b</sup>
Group 3	30.0 $\pm$ 10.8 <sup>a,b</sup>	49.50 $\pm$ 8.58 <sup>a,b</sup>
p	<0.001 <sup>†</sup>	<0.001 <sup>†</sup>

<sup>†</sup>Kruskal–Wallis test, <sup>†</sup>One-way ANOVA, <sup>a</sup>: Group 1 vs Group 3 ( $p<0.001$ ), <sup>b</sup>: Group 2 vs Group 3 ( $p<0.001$ )



**Figure 1. a-c.** Living tissue in the zone of stasis tissue in Group 1 (a), Group 2 (b), Group 3 (c) on the 7th day post-burn

1a (control group) was 21.00 ( $\pm 5.66$ ), in Group 2a (post-burn treatment group) was 27.17 ( $\pm 5.53$ ), and in Group 3a (pre-burn treatment group) was 49.50 ( $\pm 8.58$ ). When the statistical analysis was performed, it was found that the amount of autophagy in Group 3a was statistically higher than that of Group 1a and Group 2a ( $p<0.01$ ), and the amount of autophagy in Group 2a was statistically higher than Group 1a ( $p<0.01$ ) (Table 2, Figure 5).

### Determination of Cell Proliferation

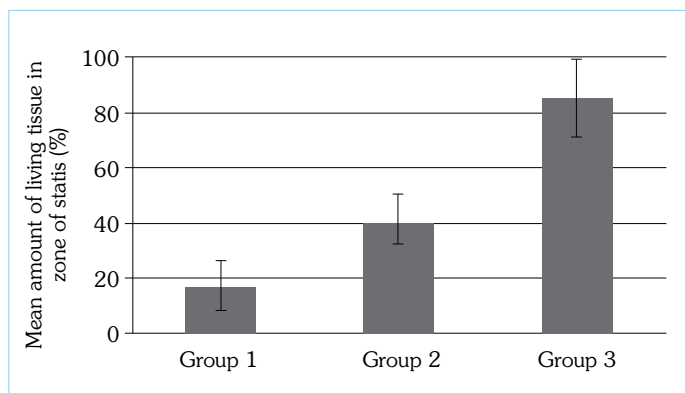
The results of the PCNA immunostimulation, which was performed to detect cellular proliferation, are shown in Table 1. In the zone of stasis, the mean number of PCNA positive cells detected in the entire epithelium, including the epidermis and epithelium of hair follicles, was 30.00 ( $\pm 10.80$ ) in Group 1b (control group), 33.80 ( $\pm 8.70$ ) in Group 2b (post-burn treatment group), and 50.40 ( $\pm 3.65$ ) in Group 3b (pre-burn treatment group). When statistically analyzed, the mean PCNA level in Group 3b was statistically significantly higher than in Groups 1b and 2b ( $p=0.019$  and  $p=0.008$ ). There was no statistically significant difference between

Groups 1b and 2b in terms of the mean PCNA levels ( $p = 0.764$ , Table 1).

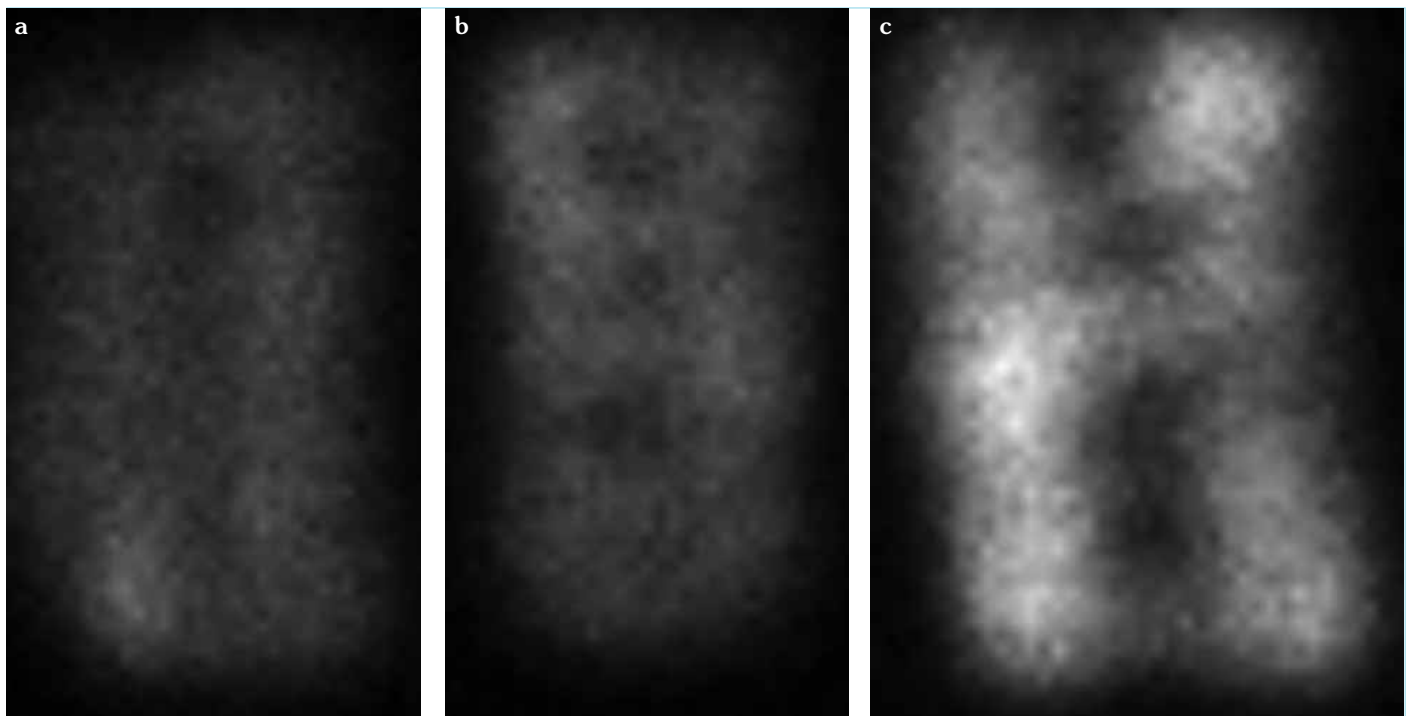
### DISCUSSION

In this study, we used the experimental model of zone of stasis, which was first described by Regas and Ehrlich (1, 11). By calculating (a) the amount of living tissue macroscopically, (b) cell proliferation immunohistochemically by PCNA, and through (c) scintigraphic examination, we showed that the quercetin treatment, especially pre-burn, statistically significantly increased the viability of tissue in the zone of stasis of a burn when compared to the control group.

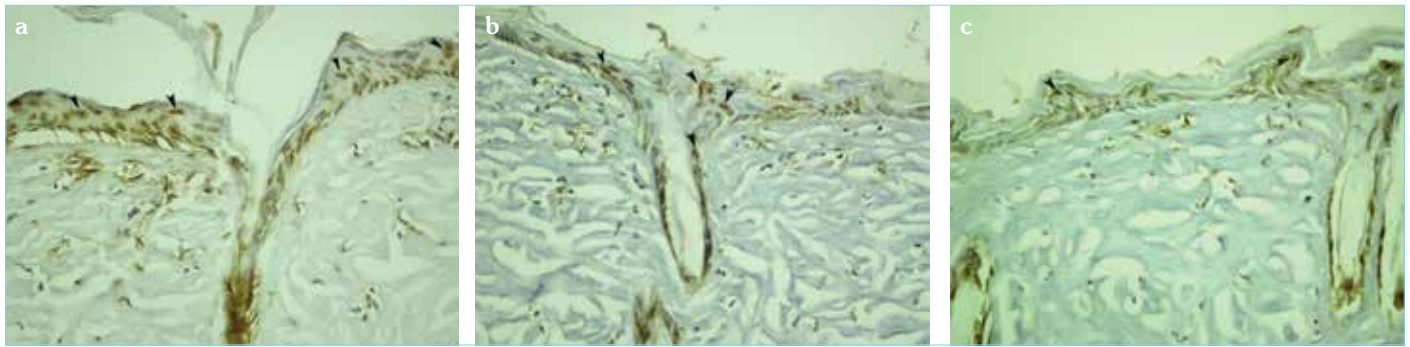
One of the main reasons for the formation of a necrotic tissue in the zone of stasis of burn injury is the accumulation of reactive oxygen radicals (ROS) and excessive inflammation. In the tissues of the zone of stasis, inflammation develops following a burn, and vascular inflammation causes clogging of the vessels. Therefore, tissue permeability decreases and tissue edema is seen. During inflammation, cytotoxic cytokines and ROS are released from the neutrophils accumulated in the environment. Due to a prolonged inflammation in burns, antioxidant mechanisms are unable to compensate for the excessive accumulation of cytokines and ROS in the environment, resulting in damage to vital structures, such as lipids, proteins, and nucleic acids. The excessive accumulation of neutrophils in the postcapillary venules during inflammation causes clogging of the vessels; therefore, there is a decrease in tissue perfusion (3). As a result, these changes cause ischemia and the death of cells in the tissue in the zone of stasis, and



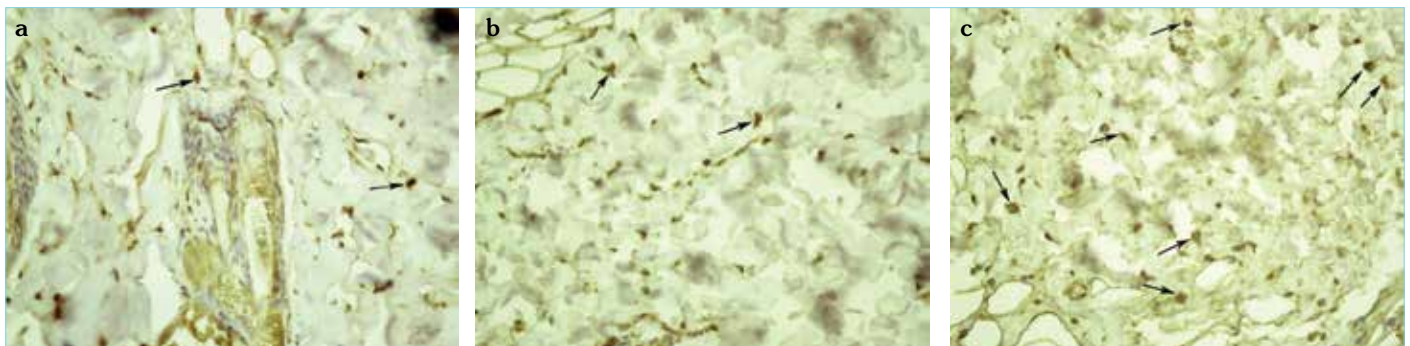
**Figure 2.** The mean amount of living tissue (%). Group 1 vs Group 2 ( $p<0.05$ ), Group 1 vs Group 3 ( $p<0.01$ ), and Group 2 vs Group 3 ( $p<0.001$ ) (one-way ANOVA)



**Figure 3.** a-c. Nuclear imaging of the rats in Group 1 (a), Group 2 (b), and Group 3 (c) on the 7th day post-burn. The zone of stasis took more radioactive agent, so the border of the zone of stasis is seen clearly in Group 3. No significant difference is seen between the zone of stasis and the zone of necrosis in Group 1.



**Figure 4. a-c.** TUNEL staining of the zone of stasis in Group 1 (a), Group 2 (b), and Group 3 (c) at 24 hours post-burn. The TUNEL positive cells were identified by intense brown nuclear staining (black arrows). Apoptotic cells were detected in the hair follicular epithelium, primarily in the surface epithelium.



**Figure 5. a-c.** Beclin staining of the zone of stasis in Group 1 (a), Group 2 (b), Group 3 (c) at 24 hours post-burn. The Beclin-positive cells are distinguished by their dark-brown-stained cytoplasm (black arrows). Autophagic cells were detected especially in the deep dermis.

a progression in the burn injury occurs (13). Tissue death from burn injuries comes in the form of necrosis and apoptosis (1). Treatments and interventions necessary to recover the tissue in the zone of stasis and to stop the progression of burn necrosis must be implemented within the first 48 hours after the burn injury (2).

Apoptosis is a type of programmed cell death. It's an organized and active process characterized by DNA fragmentation and condensation of intracellular organelles (3). In the comb burn model, which was used in this study, apoptosis can be detected in the epidermis, dermis, hair follicles, and sebaceous glands, starting from the 30th minute up until 48 hours after burn injury in the zone of stasis surrounding the burn. These apoptotic cells eventually become necrotic cells (3). Inhibiting apoptosis in the zone of stasis of a burn reduces tissue damage and increases wound healing (1).

The effect of quercetin on apoptosis varies depending on the cell type. Quercetin has an anticarcinogenic effect on leukemic cells, pancreatic tumor cells, breast cancer cells, hepatoma cells, prostate cancer cells, and stomach cancer cells, and this activity is due to its apoptotic effect on cancer cells (8, 14). Conversely, quercetin exhibits antiapoptotic activity on human keratinocytes by suppressing the production of apoptosis-regulating proteins, such as Nuclear factor (NF)- $\kappa$ B and p53 after external trauma involving thermal exposure (3, 15). In the present study, it was determined that apoptosis at the 24th hour was less with quercetin treatment,

especially with pre-burn quercetin administration, and the amount of necrosis calculated in the zone of stasis on the 7th day was also lower in the groups with a lower apoptosis level.

Autophagy, also referred to as type 2 programmed cell death, is the process of transferring intracellular macromolecule residues to lysosomes, where they are broken down into biologically active monomers, such as amino acids; this situation provide cellular metabolic turnover and homeostasis. Xiao et al. (16) showed that autophagy decreased significantly in the first 24 hours after burn injury in the zone of stasis and started increasing after 24 hours. However, it was still lower than in normal skin even 72 hours after burn injury. In the first 24 hours after burn injury, the ischemia and inflammation in the zone of stasis activate autophagy, and autophagy shows a cell-protective effect. Between 48 and 72 hours after burn injury, tissue perfusion is improved, and inflammation is decreased, parallel to increased autophagy (16). However, if the ischemia and inflammation that induces autophagy in the zone of stasis continue with the same intensity, autophagy can induce apoptosis, and tissue death can be seen (17). Therefore, although autophagy has a prosurvival role in the early stages of burn injury, it may have a late prodeath effect.

In the present study, it was determined that autophagy at the 24th hour was high with quercetin treatment, especially pre-burn quercetin administration, and the amount of necrosis calculated in the zone of stasis on the 7th day was also lower in the groups with a high autophagy level.

One of the pathways that control the autophagy formation is the mammalian target of rapamycin (mTOR) pathway, which regulates cellular homeostasis in a catabolic stress state (18). Rapamycin inhibits the mTOR kinase activity in mammals, thus stimulating autophagy. Rapamycin therapy has been shown to increase autophagy and epithelization in the zone of stasis in burns of rats (19). The mTOR pathway is also inhibited by quercetin; by doing so, it was shown that quercetin induces autophagy in the MCF7, HeLa, and MDA-MB-453 cell cultures, as seen in this present study (18).

Since our research was an experimental study, a pre-burn treatment group was also included. Our study shows that this pre-burn treatment group showed the most protective effect. Although this is not the place for clinical treatment, prophylactic treatment may be planned for employees in high-risk occupations who may be exposed to burns, such as firefighters.

## CONCLUSION

Through an evaluation by macroscopy, immunohistochemistry, and scintigraphy, this study has shown that quercetin reduces apoptosis and increases autophagy. As a result, it was demonstrated that the tissue viability increased in the zone of stasis, while the amount of necrosis also decreased.

**Ethics Committee Approval:** Ethics committee approval was received for this study from the ethics committee of Trakya University.

**Informed Consent:** N/A.

**Peer-review:** Externally peer-reviewed.

**Author Contributions:** Conceived and designed the experiments or case: EO, EŞ. Performed the experiments or case: EO, EŞ. Analyzed the data: EO, EŞ, MSM, YT. Wrote the paper: EO. All authors have read and approved the final manuscript.

**Acknowledgement:** The authors would like to thank Ramazan Uygur, Ph.D., for the provision of quercetin.

**Conflict of Interest:** The authors have no conflicts of interest to declare.

**Financial Disclosure:** The article was supported under project NKUBAP.00.20.AR.15.01 by the Namik Kemal University Research Center.

## REFERENCES

- Guo SX, Jin YY, Fang Q, You CG, Wang XG, Hu XL, et al. Beneficial effects of hydrogen-rich saline on early burn-wound progression in rats. *PLoS One* 2015; 10(4): e0124897. [\[CrossRef\]](#)
- Tan JQ, Zhang HH, Lei ZJ, Ren P, Deng C, Li XY, et al. The roles of autophagy and apoptosis in burn wound progression in rats. *Burns* 2013; 39(8): 1551-6. [\[CrossRef\]](#)
- Shupp JW, Nasabzadeh TJ, Rosenthal DS, Jordan MH, Fidler P, Jeng JC. A review of the local pathophysiologic bases of burn wound progression. *J Burn Care Res* 2010; 31(6): 849-73. [\[CrossRef\]](#)
- Uygur F, Evince R, Urhan M, Celikoz B, Haholu A. Salvaging the zone of stasis by simvastatin: an experimental study in rats. *J Burn Care Res* 2009; 30(5): 872-9. [\[CrossRef\]](#)
- Nisanci M, Eski M, Sahin I, Ilgan S, Isik S. Saving the zone of stasis in burns with activated protein C: an experimental study in rats. *Burns* 2010; 36(3): 397-402. [\[CrossRef\]](#)
- Deniz M, Borman H, Seyhan T, Haberal M. An effective antioxidant drug on prevention of the necrosis of zone of stasis: N-acetylcysteine. *Burns* 2013; 39(2): 320-5. [\[CrossRef\]](#)
- Kimura S, Warabi E, Yanagawa T, Ma D, Itoh K, Ishii Y, et al. Essential role of Nrf2 in keratinocyte protection from UVA by quercetin. *Biochem Biophys Res Commun* 2009; 387(1): 109-14. [\[CrossRef\]](#)
- Chen BL, Wang LT, Huang KH, Wang CC, Chiang CK, Liu SH. Quercetin attenuates renal ischemia/reperfusion injury via an activation of AMP-activated protein kinase-regulated autophagy pathway. *J Nutr Biochem* 2014; 25(11): 1226-34. [\[CrossRef\]](#)
- Firat C, Samdanci E, Erbatur S, Aytakin AH, Ak M, Turtay MG, et al.  $\beta$ -Glucan treatment prevents progressive burn ischaemia in the zone of stasis and improves burn healing: an experimental study in rats. *Burns* 2013; 39(1): 105-12. [\[CrossRef\]](#)
- Uylaş MU, Şahin A, Şahintürk V, Alataş İÖ. Quercetin dose affects the fate of hepatic ischemia and reperfusion injury in rats: An experimental research. *Int J Surg* 2018; 53: 117-21. [\[CrossRef\]](#)
- Kayapınar M, Seyhan N, Avunduk MC, Savacı N. Saving the zone of stasis in burns with melatonin: an experimental study in rats. *Ulus Trauma Acil Cerrahi Derg* 2015; 21(6): 419-24. [\[CrossRef\]](#)
- Uysal AC, Mizuno H, Tobita M, Ogawa R, Hyakusoku H. The effect of adipose-derived stem cells on ischemia-reperfusion injury: immunohistochemical and ultrastructural evaluation. *Plast Reconstr Surg* 2009; 124(3): 804-15. [\[CrossRef\]](#)
- Eski M, Ozer F, Firat C, Alhan D, Arslan N, Senturk T, et al. Cerium nitrate treatment prevents progressive tissue necrosis in the zone of stasis following burn. *Burns* 2012; 38(2): 283-89. [\[CrossRef\]](#)
- Wang P, Zhang K, Zhang Q, Mei J, Chen CJ, Feng ZZ, et al. Effects of quercetin on the apoptosis of the human gastric carcinoma cells. *Toxicol In Vitro* 2012; 26(2): 221-8. [\[CrossRef\]](#)
- Roshanzamir F, Yazdanparast R. Quercetin attenuates cell apoptosis of oxidant-stressed SK-N MC cells while suppressing up-regulation of the defensive element, HIF-1 $\alpha$ . *Neuroscience* 2014; 277: 780-93. [\[CrossRef\]](#)
- Xiao M, Li L, Li C, Zhang P, Hu Q, Ma L, et al. Role of autophagy and apoptosis in wound tissue of deep second-degree burn in rats. *Acad Emerg Med* 2014; 21(4): 383-91. [\[CrossRef\]](#)
- Thome RG, Santos HB, Arantes FP, Domingos FF, Bazzoli N, Rizzo E. Dual roles for autophagy during follicular atresia in fish ovary. *Autophagy* 2009; 5(1): 117-9. [\[CrossRef\]](#)
- Klappan AK, Hones S, Mylonas I, Brüning A. Proteasome inhibition by quercetin triggers macroautophagy and blocks mTOR activity. *Histochem Cell Biol* 2012; 137(1): 25-36. [\[CrossRef\]](#)
- Xiao M, Li L, Hu Q, Ma L, Liu L, Chu W, et al. Rapamycin reduces burn wound progression by enhancing autophagy in deep second-degree burn in rats. *Wound Repair Regen* 2013; 21(6): 852-9. [\[CrossRef\]](#)